



**PATIENT PRESENTING CLINICAL SIGNS**

Zeus McFarlane History: wheezing/coughing

**RADIOGRAPHIC STUDY OF THE THORAX**

**SPECIES**

The body condition score is 6/9 with smooth alternating layers of fat and soft tissue opacity.

Canine

The dorsal spinous process of vertebrae 8 and 9 is fused, the vertebral bodies short. Elbow arthrosis and lumbar spondylosis are present.

**BREED**

English Bulldog

The lungs are in contact with the thoracic boundaries and the tips are pointed. The outline of the peripheral lobar vessels is slightly blurred, the caudo-dorsal lung lobes are well expanded on both lateral views.

**SEX**

Neutered Male

The cranial mediastinum is of physiological width for the breed. The trachea diverges slightly from the thoracic vertebrae and the carina is in line with the terminal trachea.

The cardiac silhouette is slightly elevated from the sternum by a fat opacity and occupies 75% of the chest height and 3 intercostal spaces. No obvious chamber or outflow tract enlargement is evident.

**AGE**

9 Years

**RADIOGRAPHIC DIAGNOSIS**

- Mild interstitial pattern
- Well expanded caudal lung lobes

**INTERPRETED BY**

Heike Rudolf, DVM,  
Dr. med. Vet.,  
DipECVDI DVR

Incidental findings

- Elbow OA
- Spondylosis
- Block vertebrae

**HOSPITAL NAME**

The Collegeway AH

**INTERPRETATION OF THE FINDINGS & FURTHER RECOMMENDATIONS**

The well expanded lung fields in association with an interstitial pattern suggest an obstructive lung disease. Nares and soft palate should be assessed for the degree of BOAS as this may contribute to the clinical signs. Bronchoscopy will show if tracheal and/or bronchial collapse is present. A broncho-alveolar wash should be obtained to identify if inflammation or infection is present. The lung expansion makes fibrosis less likely, but changes could be present in some areas of the lung.

**REFERRING VET**

Dr. Ehab Hanna

**TECHNICAL COMMENTS**

**INVOICE**

16672

The fore legs are superimposed onto the cranial thorax.

**DATE**

7/15/22



**PATIENT**

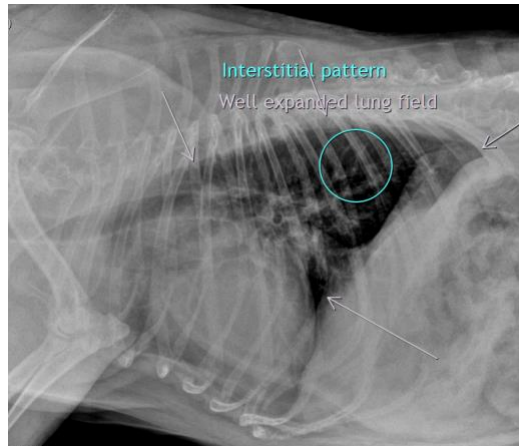
Zeus McFarlane

**SPECIES**

Canine

**BREED**

English Bulldog



**SEX**

Neutered Male

**AGE**

9 Years

**The information and recommendations provided are based on the images presented by the referring veterinarian/sonographer. No evaluation can be communicated regarding pathology that was not visible in the image/video clips provided.**

Thank you for this referral. If the clinical or image interpretation does not parallel your findings or if I can be of any further assistance please contact me.

**Heike Rudorf**, DVM, Dr. med. vet., DipECVDI, DVR  
dr.h.rudorf@gmail.com

**INTERPRETED BY**

Heike Rudorf, DVM,  
Dr. med. Vet.,  
DipECVDI DVR

**HOSPITAL NAME**

The Collegeway AH

**REFERRING VET**

Dr. Ehab Hanna

**INVOICE**

16672

**DATE**

7/15/22