



PATIENT PRESENTING CLINICAL SIGNS

Little Lulu Hourigan History: Patient Presented with difficulty breathing from a 24 hour time frame. Patient has an enlarged heart. Patient also has bloodwork pending. Loud crackles throughout but more severe on the right side.

SPECIES RADIOGRAPHIC STUDY OF THE THORAX

Canine The body condition score is 7/9 with smooth alternating layers of fat and soft tissue opacity.

Only five sternabrae are present; the xiphisternum is angled dorsally. The disc spaces vary in size.

BREED

Chihuahua The degree of pulmonary expansion is fair at best. The left lung lobes show a loss of clear vascular outline and mild bronchial enhancement. Consolidation of the right middle lobe is present. Cranial and caudal lobes on the right show an increased opacity with air-bronchograms.

SEX

The cranial mediastinum is of physiological size and opacity. The trachea runs parallel to the thoracic vertebrae and dips at the carina.

Spayed Female

The cardiac silhouette occupies 90% of the chest height and 3 intercostal spaces. The caudal heart border appears straight.

AGE RADIOGRAPHIC DIAGNOSIS

- 11
- Mixed lung infiltrate
 - Pulmonary consolidation on right

INTERPRETED BY

Incidental finding

Heike Rudolf, DVM,
Dr. med. Vet.,
DipECVDDI DVR

- Congenital sternal anomaly
- Possible disc disease

INTERPRETATION OF THE FINDINGS & FURTHER RECOMMENDATIONS

HOSPITAL NAME

Pulmonary consolidation and generalized mixed alveolar-interstitial infiltrate can be due to edema, infection, inflammation and hemorrhage. In association with a potential left sided cardiomegaly, edema is most likely. However, due to the sternal anomaly it is difficult to assess cardiac size and echocardiography is recommended to rule out/identify mitral insufficiency. Transient tracheal and/or bronchial collapse could be present and once pulmonary edema has been ruled out, this can be assessed during bronchoscopy to obtain a BAL.

Petroglyph AH

REFERRING VET

Dr. Eric Randall

INVOICE

23402

DATE

7/14/23



PATIENT

Little Lulu Hourigan

SPECIES

Canine

BREED

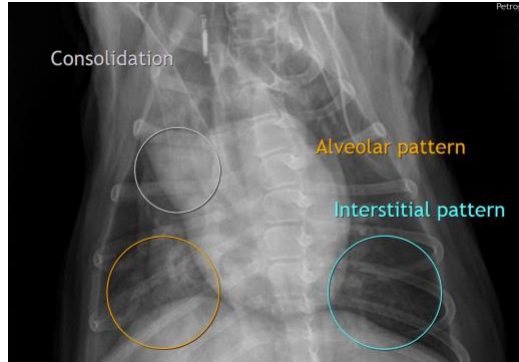
Chihuahua

SEX

Spayed Female

AGE

11



The information and recommendations provided are based on the images presented by the referring veterinarian/sonographer. No evaluation can be communicated regarding pathology that was not visible in the image/video clips provided.

Thank you for this referral. If the clinical or image interpretation does not parallel your findings or if I can be of any further assistance please contact me.

Heike Rudorf, DVM, Dr. med. vet., DipECVDI, DVR
info@sonopath.com

INTERPRETED BY

Heike Rudorf, DVM,
Dr. med. Vet.,
DipECVDI DVR

HOSPITAL NAME

Petroglyph AH

REFERRING VET

Dr. Eric Randall

INVOICE

23402

DATE

7/14/23