



PATIENT PRESENTING CLINICAL SIGNS

Abby Miller History: The family has noticed that Abby is coughing excessively when she plays hard or gets too excited for a few months now. Cough is sometimes "chuff-like" and other times "hack-like." She tested positive for heartworms twice in 2021 but had a negative echocardiogram 9-2021.

SPECIES Abnormal PE/Chem/CBC/UA Results: Cough elicited with tracheal palpation. Suspect allergic bronchitis. Treatment plan pending rad review.
Canine

RADIOGRAPHIC STUDY OF THE THORAX

BREED The body condition score is 8/9 with smooth alternating layers of fat and soft tissue opacity. Sternebra 7 is small.
Coonhound

SEX The degree of pulmonary expansion is fair at best. The lungs are in contact with the thoracic boundaries and the tips are pointed. The lobar vessels are clearly visible to the tertiary branches and have a physiological width. The bronchial tree shows mild calcification of its thin walls and tapers uniformly towards the periphery.
Spayed Female

AGE The cranial mediastinum is of physiological size and opacity. The trachea runs parallel to the thoracic vertebrae and dips at the carina. Its air-filled lumen varies in height between 0.9 and 1.7 cm and is at its lowest in the thoracic inlet.
4 Years, 4 Months

The cardiac silhouette occupies 75% of the chest height and 2.5 intercostal spaces (VHS 9.5). On the DV view the pulmonary artery segment is slightly prominent.

RADIOGRAPHIC DIAGNOSIS

- Tracheal collapse, mild

INTERPRETED BY

Heike Rudolf, DVM,
 Dr. med. Vet.,
 DipECVDDI DVR

INTERPRETATION OF THE FINDINGS & FURTHER RECOMMENDATIONS

Tracheal collapse is usually an incidental finding in large breed dogs. However, tracheal in combination with bronchial collapse may go unnoticed until physical circumstances (such as stress, running, excitement) or disease (e.g. pneumonia, bronchitis, L cardiac enlargement) reduces the ease of airflow. Bronchitis can be present without radiographic evidence and thus bronchoscopy with broncho-alveolar lavage is necessary to rule out inflammation and low-grade infection.

HOSPITAL NAME

Elizabeth AH

Echocardiography to assess mitral valve and left atrial size as well as the pulmonary outflow tract is also recommended. Should an underlying disease be present treatment may improve the clinical signs.

REFERRING VET

Kim Allyn, DVM

Obesity is known to worsen clinical signs of cough and impair lung function; weight control is recommended.

INVOICE

23403

DATE

7/14/23



PATIENT

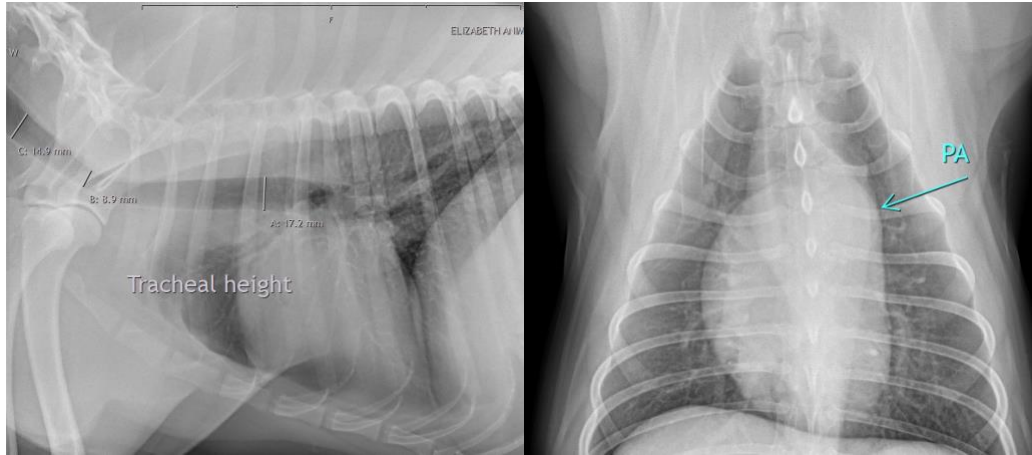
Abby Miller

SPECIES

Canine

BREED

Coonhound



SEX

Spayed Female

The information and recommendations provided are based on the images presented by the referring veterinarian/sonographer. No evaluation can be communicated regarding pathology that was not visible in the image/video clips provided.

AGE

4 Years, 4 Months

Thank you for this referral. If the clinical or image interpretation does not parallel your findings or if I can be of any further assistance please contact me.

Heike Rudorf, DVM, Dr. med. vet., DipECVDI, DVR
info@sonopath.com

INTERPRETED BY

Heike Rudorf, DVM,
Dr. med. Vet.,
DipECVDI DVR

HOSPITAL NAME

Elizabeth AH

REFERRING VET

Kim Allyn, DVM

INVOICE

23403

DATE

7/14/23