



PATIENT PRESENTING CLINICAL SIGNS

Sunie Tirado History: Sunnie presents today for limping-RFL, goes on 30-35mins walks usually but recently only wants to walk 20 mins since limping. She began to limp at the beginning of the week. No known trauma. She may have jumped off of a steep curve 3 weeks ago. Medical Hx: Nov 2019 mild right stifle arthritis.

SPECIES

Canine

RADIOGRAPHIC STUDY OF RIGHT SHOULDER, ELBOW AND PAW

The bones are well mineralized, have a normal trabecular structure and smooth, continuous surfaces.

BREED

English Bulldog

Cortical-medullary development and differentiation of the long bones are physiological.

The right shoulder joint appears congruent with even subchondral bone surfaces.

SEX

Spayed Female

With distal antebrachium and paw in a lateral position, the elbow joint is distorted and the condyles are not superimposed onto one another. The right elbow joint appears to be incongruent and smooth new bone formation is present on condyles, radial head, anconeal process and medial coronoid process. A large bone spur extends lateral from the lateral epicondyle.

AGE

9

Paws: sesamoid bones 5 and 7 are bi- or multi-partite respectively. The carpal joints are congruent.

RADIOGRAPHIC DIAGNOSIS

- Elbow OA, moderate
- Sesamoid bone abnormalities (incidental finding)

INTERPRETED BY

Heike Rudorf, DVM,
Dr. med. Vet.,
DipECVDDI DVR

INTERPRETATION OF THE FINDINGS & FURTHER RECOMMENDATIONS

I feel it is likely that the elbow changes are the cause for the lameness. The bony changes are chronic but a soft tissue trauma, e.g. due to an altered gait, could have led to a myositis. Contrast CT is recommended so that a myositis can be identified. Treatment with local steroids may be beneficial.

HOSPITAL NAME

DTLAvets

REFERRING VET

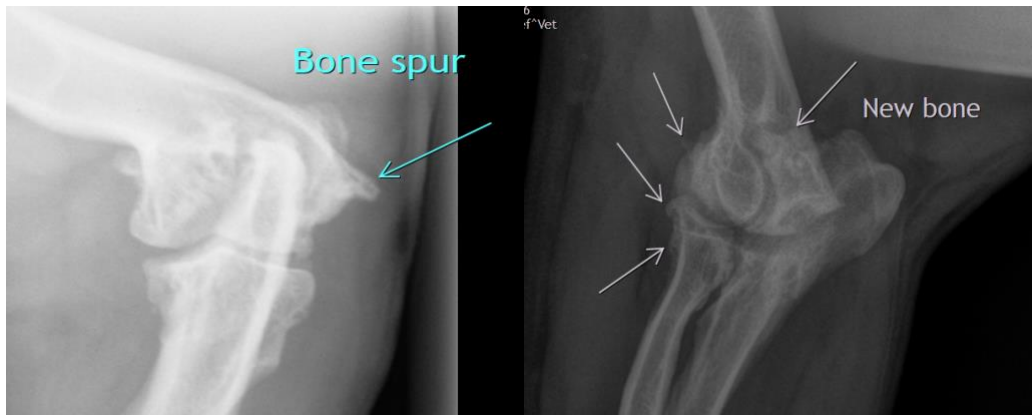
Dr. Montoya

INVOICE

23366

DATE

7/13/23





PATIENT

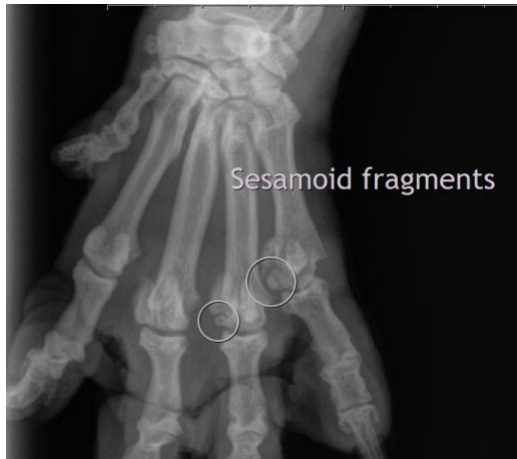Sunie Tirado

SPECIES

Canine

BREED

English Bulldog



SEX

Spayed Female

The information and recommendations provided are based on the images presented by the referring veterinarian/sonographer. No evaluation can be communicated regarding pathology that was not visible in the image/video clips provided.

AGE

9

Thank you for this referral. If the clinical or image interpretation does not parallel your findings or if I can be of any further assistance please contact me.

Heike Rudorf, DVM, Dr. med. vet., DipECVDI, DVR
info@sonopath.com

INTERPRETED BY

Heike Rudorf, DVM,
Dr. med. Vet.,
DipECVDI DVR

HOSPITAL NAME

DTLAvets

REFERRING VET

Dr. Montoya

INVOICE

23366

DATE

7/13/23