



**PATIENT PRESENTING CLINICAL SIGNS**

Moses Gerbino History: Acute limping for 3 days in the back left leg

**RADIOGRAPHIC STUDY OF THE STIFLES**

**SPECIES Left Stifle**

Canine The muscle mass on the lateral aspect of femur and tibia appears slightly reduced.

**BREED** Smooth subchondral bone surfaces are present and the centre of the femoral condyles is in line with the intercondylar eminence. The cranial fat pad appears to be reduced from caudally. The caudal fascial plains are in a physiological position. New bone formation is not evident and the patella is superimposed onto the left condyle.

French Bulldog

**Right Stifle**

**SEX**

Neutered Male Smooth subchondral bone surfaces are present and the centre of the femoral condyles is in line with the intercondylar eminence. The cranial fat pad has a physiological size and the caudal fascial plains are in a physiological position. New bone formation is not evident and the patellae is superimposed onto the left condyle.

**AGE**

11 Months The tail shows block-, wedge- and other congenital anomalies consistent with a screw tail.

**RADIOGRAPHIC DIAGNOSIS**

**INTERPRETED BY**

Heike Rudorf, DVM,  
Dr. med. Vet.,  
DipECVDI DVR

- Bilateral HD, severe
- Bilateral OA, moderate
- Muscle atrophy left, mild
- Possible stifle effusion left, mild

Incidental finding

**HOSPITAL NAME**

Rockaway AH

- Congenital anomalies tail

**INTERPRETATION OF THE FINDINGS & FURTHER RECOMMENDATIONS**

**REFERRING VET**

Dr. Bednar

Severe bilateral hip dysplasia is present. The subjective muscle atrophy on the left should be confirmed with a tape measure. Should it be real, it is due to a process which is older than 3 days. The impression of a left sided joint effusion could be due to the superimposed outline of the prepuce or a true finding after a trauma. I feel that the HD is the most likely reason for the lameness. It could have resulted in alteration of the gait which in turn has led to a stifle joint injury. The radiographic findings have to be viewed in combination with the findings from the orthopedic examination.

**INVOICE**

23364

**DATE**

7/13/23



**PATIENT**

Moses Gerbino

**SPECIES**

Canine

**BREED**

French Bulldog

**SEX**

Neutered Male

**AGE**

11 Months

**INTERPRETED BY**

Heike Rudolf, DVM,  
Dr. med. Vet.,  
DipECVDI DVR

**HOSPITAL NAME**

Rockaway AH

**REFERRING VET**

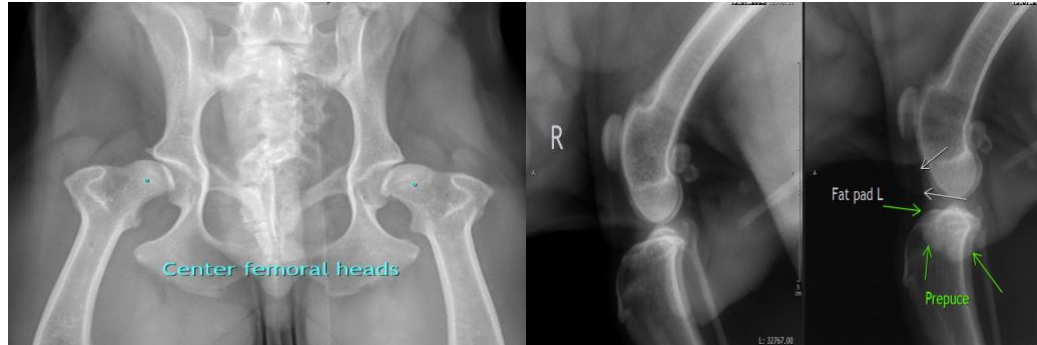
Dr. Bednar

**INVOICE**

23364

**DATE**

7/13/23



**The information and recommendations provided are based on the images presented by the referring veterinarian/sonographer. No evaluation can be communicated regarding pathology that was not visible in the image/video clips provided.**

Thank you for this referral. If the clinical or image interpretation does not parallel your findings or if I can be of any further assistance please contact me.

**Heike Rudolf**, DVM, Dr. med. vet., DipECVDI, DVR  
info@sonopath.com