



PATIENT PRESENTING CLINICAL SIGNS

THAI HARDING History: Patient presented 6/30/22 for wellness exam, patient has a history of left hind cruciate injury in October 2021. Owner temporarily managed injury with custom "My Pet's Brace" but has not been using recently. Owner also noted that brace no longer fits correctly due to hard thickening changes at proximal tibia. Patient's appetite has been picky with age, however still drinking/urinating/defecating within normal limits.

SPECIES

Canine

BREED

Lab Mix

Abnormal PE/Chem/CBC/UA Results: New anaplasmosis infection diagnosed at recent exam. Firm swelling palpated medially of distal stifle joint- painful to touch. Elevated GLOB 4.6g/dL (2.5-4.5), otherwise blood panel was nonremarkable.

RADIOGRAPHIC STUDY OF THE STIFLES

SEX

Spayed Female

The left stifle joint has smooth subchondral bone surfaces and the centre of the femoral condyles is located caudal to the intercondylar eminence. The cranial fat pad is reduced and the caudal fascial plains are caudally displaced by a soft tissue opacity within the joint. A mild to moderate amount of new bone formation is present on the lateral femoral condyle, the femoral ridges, patella and tibial plateau. The muscle mass on the left side appears to be reduced.

AGE

11 Years 11 Months

RADIOGRAPHIC DIAGNOSIS

Left stifle

- Cruciate ligament rupture and moderate OA

INTERPRETED BY

Heike Rudorf, DVM,
Dr. med. Vet.,
DipECVDDI DVR

INTERPRETATION OF THE FINDINGS & FURTHER RECOMMENDATIONS

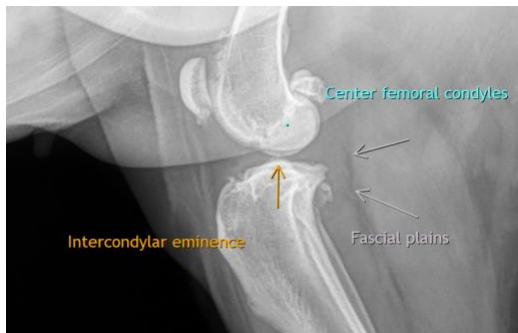
The radiographic changes are compatible with the previously diagnosed cruciate rupture. The described painful swelling should be further examined with ultrasound to see if fluid (e.g. abscess) is present. A sample should be obtained to rule out a soft tissue tumour

HOSPITAL NAME

Pocono Peak VC

REFERRING VET

Dr. Nicole Norris
Carney



INVOICE

16467

The information and recommendations provided are based on the images presented by the referring veterinarian/sonographer. No evaluation can be communicated regarding pathology that was not visible in the image/video clips provided.

DATE

7/1/22



PATIENT

Thai Harding

Thank you for this referral. If the clinical or image interpretation does not parallel your findings or if I can be of any further assistance please contact me.

SPECIES

Canine

Heike Rudolf, DVM, Dr. med. vet., DipECVDI, DVR
dr.h.rudorf@gmail.com

BREED

Lab Mix

SEX

Spayed Female

AGE

11 Years 11 Months

INTERPRETED BY

Heike Rudolf, DVM,
Dr. med. Vet.,
DipECVDI DVR

HOSPITAL NAME

Pocono Peak VC

REFERRING VET

Dr. Nicole Norris
Carney

INVOICE

16467

DATE

7/1/22