



PATIENT PRESENTING CLINICAL SIGNS

Willow Barker History: Hematuria
Abnormal PE/Chem/CBC/UA Results: Heart murmur heart rate 180-200 B/m

SPECIES RADIOGRAPHIC STUDY OF THE THORAX

Feline The body condition score is 8/9 with smooth alternating layers of fat and soft tissue opacity. The ventral abdominal wall is pendulous.

BREED Mild spondylosis is present ventral to T10/11.

DSH The lungs are in contact with the thoracic boundaries and the tips of the caudal lobes are pointed; the cranial lobar edges are rounded. On the VD some peripheral bronchi are highlighted.

SEX The cranial mediastinum is of physiological size and opacity. The trachea runs parallel to the thoracic vertebrae and dips at the carina. A small amount of air is present in the esophagus.
Spayed Female

AGE The cardiac silhouette occupies 75% of the chest height and 2 intercostal spaces. No chamber or outflow tract enlargement is obvious. Though on the VD view the left cardiac silhouette appears to have a double outline.

8 Years

RADIOGRAPHIC DIAGNOSIS

- INTERPRETED BY**
- Mild interstitial pattern
 - Double outline left cardiac silhouette
 - Obesity
 - Spondylosis, mild
- Heike Rudorf, DVM,
Dr. med. Vet.,
DipECVDDI DVR

INTERPRETATION OF THE FINDINGS & FURTHER RECOMMENDATIONS

HOSPITAL NAME The double outline of the heart is most likely the result of an increased amount of pericardial fat. The mild interstitial pattern could be due to a previous right lateral recumbency with insufficient re-aeration of the alveoli, especially in association with obesity. As a heart murmur is present, echocardiography is recommended to identify if hypertrophic cardiomyopathy is present.
St. Catharines AH

Possible differential diagnoses for a true interstitial infiltrate include:

- REFERRING VET**
- Edema
 - Infection (bacterial, fungal, parasitic)
 - Inflammation (e.g. allergic)
 - Fibrosis
 - Tumor (e.g. lymphoma)
- Dr Mena

INVOICE

15985 Further evaluation by means of tracheobronchoscopy with bronchoalveolar lavage is recommended. Obesity is known to worsen clinical signs of cough and impair lung function; weight control is strongly advised.

DATE

6/9/22



PATIENT

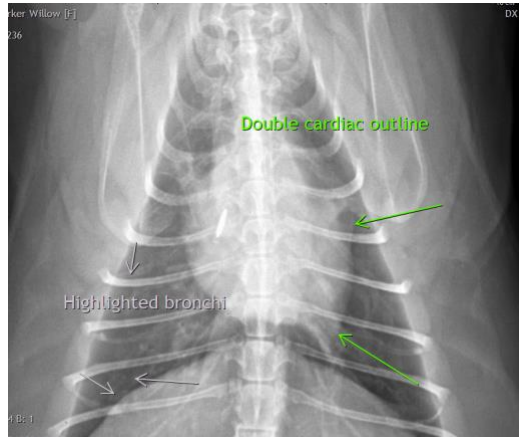
Willow Barker

SPECIES

Feline

BREED

DSH



SEX

Spayed Female

The information and recommendations provided are based on the images presented by the referring veterinarian/sonographer. No evaluation can be communicated regarding pathology that was not visible in the image/video clips provided.

AGE

8 Years

Thank you for this referral. If the clinical or image interpretation does not parallel your findings or if I can be of any further assistance please contact me.

Heike Rudolf, DVM, Dr. med. vet., DipECVDI, DVR
dr.h.rudorf@gmail.com

INTERPRETED BY

Heike Rudolf, DVM,
Dr. med. Vet.,
DipECVDI DVR

HOSPITAL NAME

St. Catharines AH

REFERRING VET

Dr Mena

INVOICE

15985

DATE

6/9/22