



PATIENT PRESENTING CLINICAL SIGNS

T2 White History: The ear issue was last discussed at the 11-21 wellness. Angie is concerned because one of the house mates licks T2's ear until they are soggy and she is concerned he has an ear infection. The husband cleans the ears with wash but Angie isn't sure if it is one ear or both. T2 has been having some weight loss, and Angie says that the lymph nodes feel large to her. She hasn't changed foods or amount. She says his energy levels are down. Angie says he has been vomiting.

SPECIES

Canine

BREED

Labrador Retriever Mix

Abnormal PE/Chem/CBC/UA Results: HARSH LUNG SOUNDS INCREASED EFFORT/ABDOMINAL PRESS BILATERAL EAR INFECTION MASS/THICKENING TO SOFT PALATE SUBMANDIBULAR LN ENLARGED AND FIRM

RADIOGRAPHIC STUDY OF THORAX AND NECK

Thorax

SEX

The body condition score is 4/9.

Male

The bony structures appear physiological.

AGE

11 Years 5 Months

A generalized nodular infiltrate is present with most nodule up to pea size. Dorsal to sternebra 6 a 2.4cm soft tissue mass is evident. Some doughnuts are present.

The cranial mediastinum is of physiological size and opacity. The trachea diverges slightly from the thoracic vertebrae and dips at the carina.

INTERPRETED BY

Heike Rudolf, DVM,
Dr. med. Vet.,
DipECVDI DVR

The cardiac silhouette occupies 75% of the chest height and 2 intercostal spaces. No chamber or outflow tract enlargement is evident.

Abdomen

HOSPITAL NAME

Elizabeth AH

Soft tissue masses are not obvious. No signs of aggressive osteolysis have been identified.

RADIOGRAPHIC DIAGNOSIS

- Pulmonary nodules

REFERRING VET

Kim Allyn, DVM

INTERPRETATION OF THE FINDINGS & FURTHER RECOMMENDATIONS

Number, shape and size of the pulmonary nodules are compatible with metastases, granulomata present a less likely differential diagnosis. The nodules may be caused by an external ear canal tumour. This would explain a mandibular lymphadenomegaly and the licking by the other dog. A contrast CT examination would be the method of choice for finding a tumor.

INVOICE

15984

DATE

6/9/22



PATIENT

T2 White

SPECIES

Canine

BREED

Labrador Retriever
Mix

SEX

Male

AGE

11 Years 5 Months

INTERPRETED BY

Heike Rudolf, DVM,
Dr. med. Vet.,
DipECVDI DVR

HOSPITAL NAME

Elizabeth AH

REFERRING VET

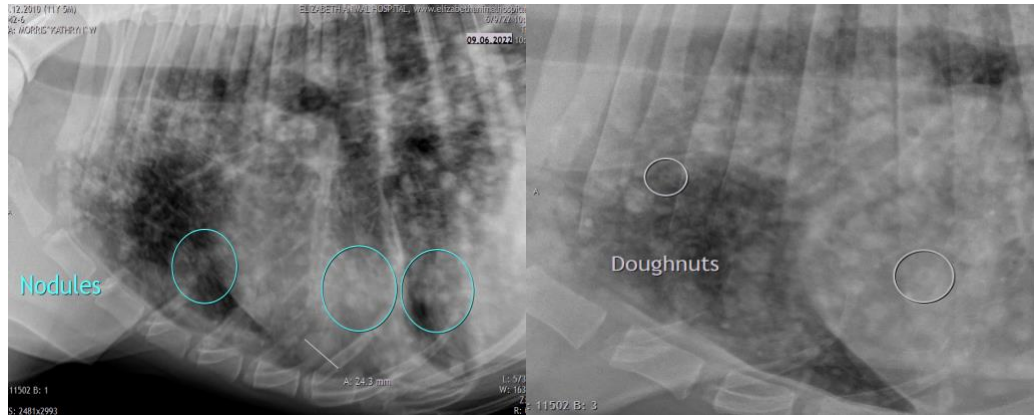
Kim Allyn, DVM

INVOICE

15984

DATE

6/9/22



The information and recommendations provided are based on the images presented by the referring veterinarian/sonographer. No evaluation can be communicated regarding pathology that was not visible in the image/video clips provided.

Thank you for this referral. If the clinical or image interpretation does not parallel your findings or if I can be of any further assistance please contact me.

Heike Rudolf, DVM, Dr. med. vet., DipECVDI, DVR
dr.h.rudorf@gmail.com