

**PATIENT**

Stevie Nicks Garcia

PRESENTING CLINICAL SIGNS

Patient had previous radiographs sent for review on Saturday May 7th, 2022. Suggested a presence of a soft tissue injury in the neck area, recommended to recheck radiographs in 2-4 weeks.

SPECIES

K9

RADIOGRAPH OF THE THORAX

RLR, LLR, VD

BREED

Chihuahua Mix

RADIOGRAPHIC FINDINGS

The two series are compared. The costochondral junction of the two ribs of each vertebra are separated by approx. 1cm and previously by approx. 2 cm on the right lateral recumbent views. The nodules described previously appear identical. A third nodule is located just ventral to the caudal endplate of T5.

SEX

FS

The thoracic organs are otherwise physiological.

The cervical soft tissue structures appear physiological.

RADIOGRAPHIC DIAGNOSIS**AGE**

7 Years

- Similar to previous study

INTERPRETED BY

Heike Rudolf, DVM,
Dr. med. Vet.,
DipECVDI DVR

INTERPRETATION OF THE FINDINGS & FURTHER RECOMMENDATIONS

The visibility of the third lung nodule is most likely due to the lesser degree of thoracic tilting. The unchanged size of the other two nodules is compatible with benign changes such as granuloma, fibrosis or polyp.

HOSPITAL NAME

DTLAvets

REFERRING VET

Dr. Castaneda

INVOICE

52395

DATE

6-9-22



PATIENT

Stevie Nicks Garcia

SPECIES

K9

BREED

Chihuahua Mix

SEX

FS

AGE

7 Years

INTERPRETED BY

Heike Rudorf, DVM,
Dr. med. Vet.,
DipECVDI DVR

HOSPITAL NAME

DTLAvets

REFERRING VET

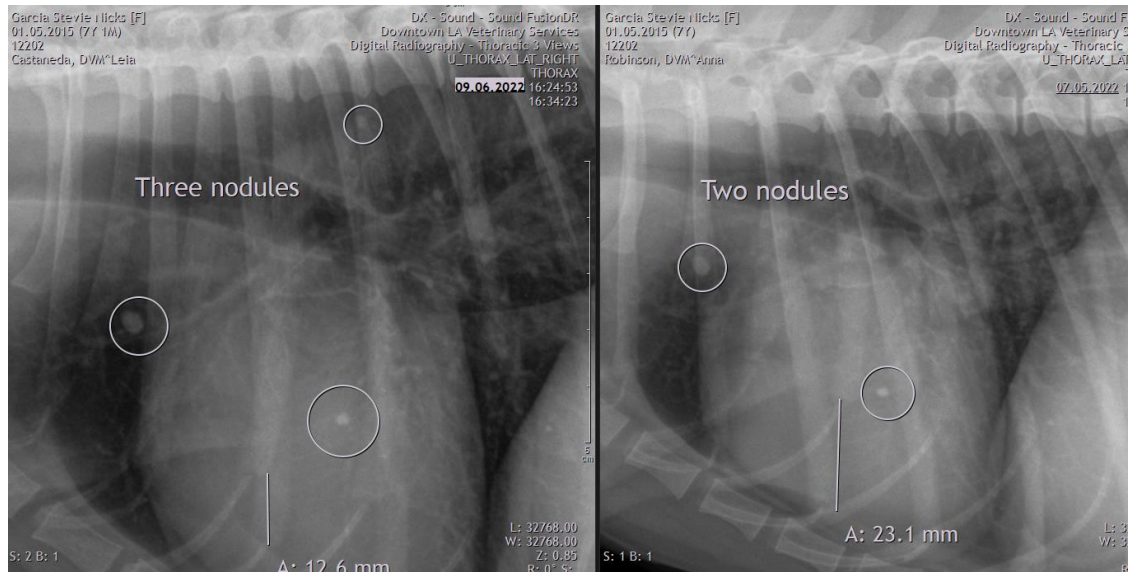
Dr. Castaneda

INVOICE

52395

DATE

6-9-22



The information and recommendations provided are based on the images presented by the referring veterinarian/sonographer. No evaluation can be communicated regarding pathology that was not visible in the image/video clips provided.

Thank you for this referral. If the clinical or image interpretation does not parallel your findings or if I can be of any further assistance please contact me.

Heike Rudorf, DVM, Dr. med. vet., DipECVDI, DVR
Dr.H.Rudorf@gmail.com