



PATIENT PRESENTING CLINICAL SIGNS

Outlaw Smith History: Pt presented for limping on left hind starting this morning. O didn't see him fall or any trauma. Pt doing well otherwise. Pt sedated for xrays. After sedation: limited drawer sign and limited anterior thrust.

SPECIES RADIOGRAPHIC STUDY OF THE STIFLES

Canine

The left stifle joint has smooth subchondral bone surfaces and the centre of the femoral condyles is in line with the intercondylar eminence. The cranial fat pad has a physiological size, and the caudal fascial plains are in a physiological position though mildly compressed. A small bone spur appears to be present on the supracondylar tuberosity. The patella is located in its groove.

BREED

Australian Shepherd

SEX

Male

RADIOGRAPHIC DIAGNOSIS

- Possible small amount of caudal joint fluid
- Bone spur supracondylar tuberosity

AGE

1.5 Years

INTERPRETATION OF THE FINDINGS & FURTHER RECOMMENDATIONS

The radiographic findings do not suggest cruciate disease but if a cranial drawer sign is present on the affected leg only, this is still a possibility. The bone spur could represent gastrocnemius pathology. Should conservative treatment not result in an improvement of the clinical signs, radiographs can be repeated, or a contrast CT examination carried out to rule out enthesiopathy or myositis of the gastrocnemius muscle belly/-ies.

INTERPRETED BY

Heike Rudolf, DVM,
Dr. med. Vet.,
DipECVDDI DVR

HOSPITAL NAME

The PH of Stratford

REFERRING VET

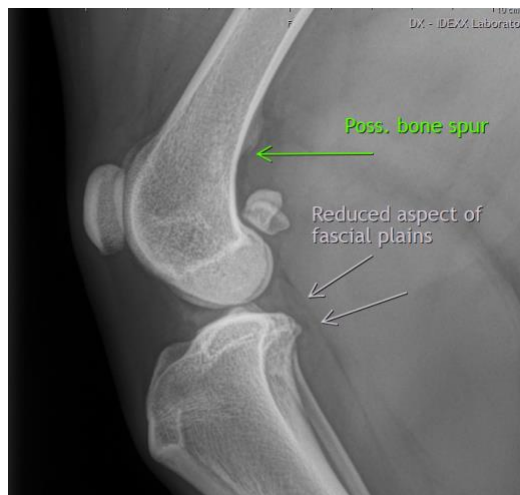
Dr. Robert Baskin

INVOICE

15983

DATE

6/9/22





PATIENT

Outlaw Smith

The information and recommendations provided are based on the images presented by the referring veterinarian/sonographer. No evaluation can be communicated regarding pathology that was not visible in the image/video clips provided.

SPECIES

Canine

Thank you for this referral. If the clinical or image interpretation does not parallel your findings or if I can be of any further assistance please contact me.

Heike Rudolf, DVM, Dr. med. vet., DipECVDI, DVR
dr.h.rudorf@gmail.com

BREED

Australian Shepherd

SEX

Male

AGE

1.5 Years

INTERPRETED BY

Heike Rudolf, DVM,
Dr. med. Vet.,
DipECVDI DVR

HOSPITAL NAME

The PH of Stratford

REFERRING VET

Dr. Robert Baskin

INVOICE

15983

DATE

6/9/22