



PATIENT PRESENTING CLINICAL SIGNS

Gabby Begalle History: Murmur, recent cough, possible syncope or seizure

RADIOGRAPHIC STUDY OF THE THORAX

SPECIES

Canine The body condition score is 8/9 with smooth alternating layers of fat and soft tissue opacity.

Canine

A dorsal deviation is present at the thoraco-lumbar (TL) junction. The sternum is located well to the left of the thoracic spine on the DV view.

BREED

Chihuahua The degree of pulmonary expansion is fair at best. The lungs are in contact with the thoracic boundaries and the tips are pointed. The lobar vessels in the right caudal lobe are slightly blurred and bronchi are highlighted.

SEX

Spayed Female The cranial mediastinum is of physiological size and opacity. The trachea runs parallel to the thoracic vertebrae and is in line with the carina.

AGE

15 Years 6 Months The cardiac silhouette occupies 90% of the chest height and 3.5 intercostal spaces. Both cranial and caudal borders are rounded.

RADIOGRAPHIC DIAGNOSIS

INTERPRETED BY

- Localized interstitial pattern
- Hepatomegaly, very mild
- Possible intervertebral disc disease at TL junction

Heike Rudolf, DVM,
Dr. med. Vet.,
DipECVDI DVR

INTERPRETATION OF THE FINDINGS & FURTHER RECOMMENDATIONS

HOSPITAL NAME

Stuga North VC The cardiac size appears physiological but early mitral endocardiosis and regurgitation should be ruled out with echocardiography. Tracheal collapse is not visible but the gold standard for its identification is tracheoscopy; this would also allow the identification of the bronchi for collapse which may coexist with tracheal collapse or be present alone. The lobar appearance of an interstitial infiltrate could represent an artefact due to incomplete lung re-expansion after previous right lateral recumbency. Possible differential diagnoses for a true infiltrate include early:

REFERRING VET

- Dr. Pesola
- Edema
 - Infection (bacterial, fungal e.g. candida, viral, Rickettsia, Spirochetes, parasitic)
 - Inflammation (allergic e.g. eosinophilic bronchopneumonia and PIE, smoke inhalation)
 - Hemorrhage (less likely)

INVOICE

15978 Obesity is a known to worsen clinical signs of cough and impair lung function; weight control is strongly recommended.

DATE

6/9/22



PATIENT TECHNICAL COMMENTS

Gabby Begalle Non-DICOM images were submitted. The transformation from DICOM to other formats reduces the image quality and only allows limited manipulation of the image. More subtle lesions can thus easily be missed. For the best possible imaging reports, I suggest submitting DICOM images in the future.

SPECIES

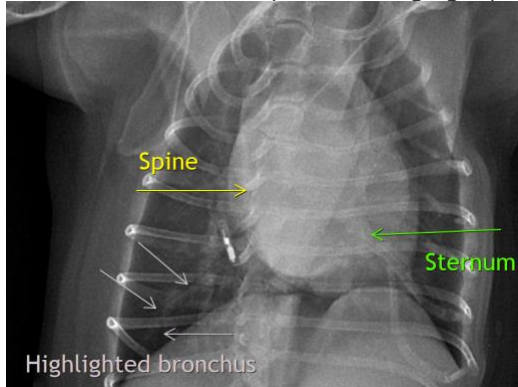
Canine

BREED

Chihuahua

SEX

Spayed Female



The information and recommendations provided are based on the images presented by the referring veterinarian/sonographer. No evaluation can be communicated regarding pathology that was not visible in the image/video clips provided.

AGE

15 Years 6 Months

Thank you for this referral. If the clinical or image interpretation does not parallel your findings or if I can be of any further assistance please contact me.

INTERPRETED BY

Heike Rudolf, DVM, Dr. med. vet., DipECVDI, DVR
dr.h.rudorf@gmail.com

Heike Rudolf, DVM,
Dr. med. Vet.,
DipECVDI DVR

HOSPITAL NAME

Stuga North VC

REFERRING VET

Dr. Pesola

INVOICE

15978

DATE

6/9/22