



PATIENT PRESENTING CLINICAL SIGNS

Toby Small History: hacking cough
Abnormal PE/Chem/CBC/UA Results: CBC and chem results WNL

SPECIES RADIOGRAPHIC STUDY OF THE THORAX

Canine The body condition score is 6/9 with smooth alternating layers of fat and soft tissue opacity.
The bony structures appear physiological.

BREED The degree of pulmonary expansion is fair at best due to the large amount of food in the stomach. The lungs are in contact with the thoracic boundaries and the tips are pointed. The lobar vessels are visible.
Spaniel X The cranial mediastinum is of physiological size and opacity. The trachea diverges from the thoracic vertebrae and the carina is located at T5. A dorsal soft tissue opacity halves the tracheal air shadow in the thoracic inlet.

SEX Neutered Male
The cardiac silhouette occupies 75% of the chest height and 2.5 intercostal spaces (VHS11). The caudal border is straight and mild tenting of the left atrium (LA) appears to be present. On the VD view the left main stem bronchus is cranially displaced, whereas the right curves around the left atrium.

AGE RADIOGRAPHIC DIAGNOSIS

11 Years

- Tracheal collapse
- Possible left cardiac enlargement

INTERPRETED BY INTERPRETATION OF THE FINDINGS & FURTHER RECOMMENDATIONS

Heike Rudorf, DVM, Dr. med. Vet., DipECVDDI DVR Tracheal collapse alone can be due to a weakened dorsal tracheal ligament. Tracheal in combination with bronchial collapse is usually due to an altered cartilage development which may go unnoticed until physical circumstances (such as stress, running, excitement) or disease (e.g. L cardiac enlargement, pneumonia, bronchitis) reduces the ease of airflow. Echocardiography to assess mitral valve and left atrial size as well as bronchoscopy to obtain a BAL is recommended. Should an underlying disease be present treatment may improve the clinical signs.

HOSPITAL NAME

Balmy Beach PH

REFERRING VET

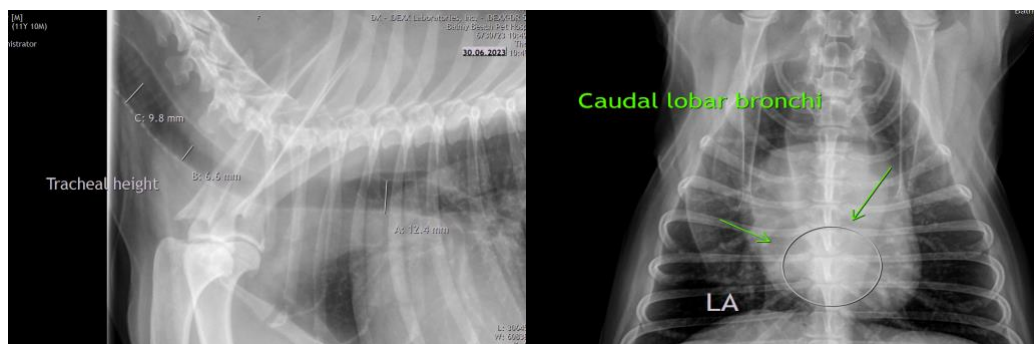
Dr. Singh

INVOICE

23153

DATE

6/30/23





PATIENT The information and recommendations provided are based on the images presented by the referring veterinarian/sonographer. No evaluation can be communicated regarding pathology that was not visible in the image/video clips provided.

Toby Small

Thank you for this referral. If the clinical or image interpretation does not parallel your findings or if I can be of any further assistance please contact me.

SPECIES

Canine **Heike Rudolf**, DVM, Dr. med. vet., DipECVDI, DVR
info@sonopath.com

BREED

Spaniel X

SEX

Neutered Male

AGE

11 Years

INTERPRETED BY

Heike Rudolf, DVM,
Dr. med. Vet.,
DipECVDI DVR

HOSPITAL NAME

Balmy Beach PH

REFERRING VET

Dr. Singh

INVOICE

23153

DATE

6/30/23