



PATIENT PRESENTING CLINICAL SIGNS

Muddy Kernohan History: Sneezing and sneezing blood

RADIOGRAPHIC STUDY OF THE HEAD

SPECIES

Feline The bones of the skull are well mineralized and have smooth borders. Both bullae are air filled and thin walled. Both nasal chambers contain air and the turbinate structure appears symmetrical. The visible tooth roots appear physiological.

BREED RADIOGRAPHIC DIAGNOSIS

Scottish Fold • I can see no nasal abnormalities

INTERPRETATION OF THE FINDINGS & FURTHER RECOMMENDATIONS

SEX

Neutered Male I can see no abnormalities. Rhinoscopy is recommended to identify early destructive changes to obtain a biopsy. Alternatively, a CT examination can be performed. Coagulation should be checked.

AGE

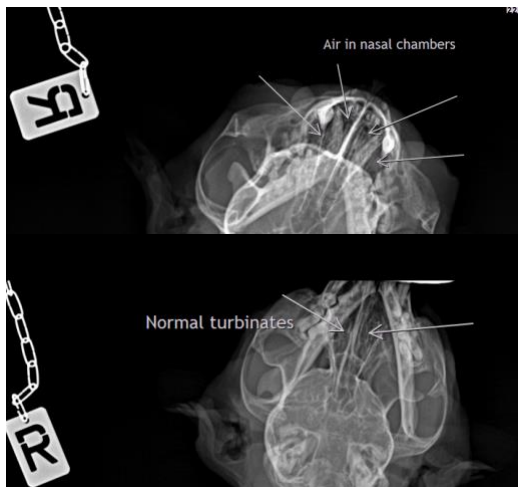
2 Years

INTERPRETED BY

Heike Rudolf, DVM,
Dr. med. Vet.,
DipECVDI DVR

HOSPITAL NAME

Truscott AH



The information and recommendations provided are based on the images presented by the referring veterinarian/sonographer. No evaluation can be communicated regarding pathology that was not visible in the image/video clips provided.

REFERRING VET

Dr. Medhat Meawad

Thank you for this referral. If the clinical or image interpretation does not parallel your findings or if I can be of any further assistance please contact me.

INVOICE

16311

Heike Rudolf, DVM, Dr. med. vet., DipECVDI, DVR
dr.h.rudorf@gmail.com

DATE

6/24/22



PATIENT

Muddy Kernohan

SPECIES

Feline

BREED

Scottish Fold

SEX

Neutered Male

AGE

2 Years

INTERPRETED BY

Heike Rudolf, DVM,
Dr. med. Vet.,
DipECVDI DVR

HOSPITAL NAME

Truscott AH

REFERRING VET

Dr. Medhat Meawad

INVOICE

16311

DATE

6/24/22