



**PATIENT PRESENTING CLINICAL SIGNS**

Petunia Hemmings History: chronic cough, progressive dyspnea, r/o pulmonary nodules, metastatic cancer

**RADIOGRAPHIC STUDY OF THE THORAX**

**SPECIES** The body condition score is approx. 6/9 with smooth alternating layers of fat and soft tissue opacity. Ventral spondylosis is especially prominent on the caudal thoracic vertebrae. The ribs are straight and parallel to each other.  
Canine

**BREED** The entire lung field contains nodule opacities of variable diameter. Especially in the right caudal lung lobe they are confluent and form larger mass lesions.

American Bulldog Mix The cranial mediastinum is of physiological size and opacity. The trachea runs parallel to the thoracic vertebrae and dips acutely at the carina.

**SEX** The cardiac silhouette occupies approx. 80% of the chest height and 3 intercostal spaces. No chamber or outflow tract enlargement is evident.

Spayed Female

**RADIOGRAPHIC DIAGNOSIS**

- Pulmonary metastases
- Bronchial lymphadenopathy
- Dyspnea
- Spondylosis (incidental finding)

11 Years 11 Months

**INTERPRETATION OF THE FINDINGS & FURTHER RECOMMENDATIONS**

**INTERPRETED BY** Multiple nodular opacities of variable diameter are due to metastases. Granulomata can also create nodules but rarely to the degree depicted here. The ventrally depressed carina indicated peri-bronchial lymph node enlargement which is often associated with metastatic tumor spread. The path of the trachea parallel to the vertebrae can be due to mediastinal lymphadenomegaly or could be due to the breed related chest conformation. The orientation of the ribs indicates dyspnea.

Heike Rudolf, DVM,  
Dr. med. Vet.,  
DipECVDI DVR

**HOSPITAL NAME**

Green Dog Dental & Wellness

**REFERRING VET**

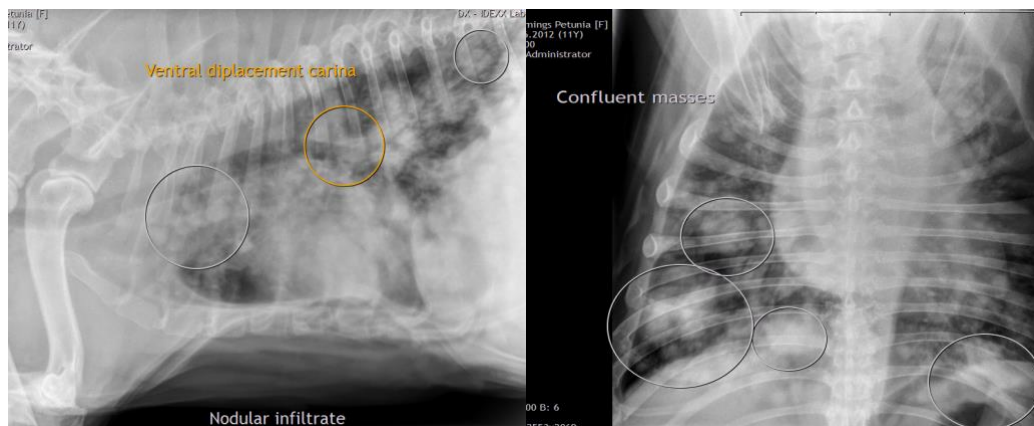
Dr. Geist

**INVOICE**

23010

**DATE**

6/23/23





**PATIENT**

Petunia Hemmings

**The information and recommendations provided are based on the images presented by the referring veterinarian/sonographer. No evaluation can be communicated regarding pathology that was not visible in the image/video clips provided.**

**SPECIES**

Canine

Thank you for this referral. If the clinical or image interpretation does not parallel your findings or if I can be of any further assistance please contact me.

**Heike Rudolf**, DVM, Dr. med. vet., DipECVDI, DVR  
info@sonopath.com

**BREED**

American Bulldog Mix

**SEX**

Spayed Female

**AGE**

11 Years 11 Months

**INTERPRETED BY**

Heike Rudolf, DVM,  
Dr. med. Vet.,  
DipECVDI DVR

**HOSPITAL NAME**

Green Dog Dental &  
Wellness

**REFERRING VET**

Dr. Geist

**INVOICE**

23010

**DATE**

6/23/23