



PATIENT PRESENTING CLINICAL SIGNS

Diesel Morelock History: Weight loss, ataxic, weak, knuckling.

RADIOGRAPHIC STUDY OF THE NECK

SPECIES Number and shape of the vertebrae are physiological.

Canine The facet joints are congruent.

BREED No signs of aggressive osteolysis have been identified.

RADIOGRAPHIC DIAGNOSIS

Min Pin

- I can see no cause for the clinical signs

SEX INTERPRETATION OF THE FINDINGS & FURTHER RECOMMENDATIONS

Neutered Male Accurate positioning of the spine is difficult, even under G.A., and cord compression can only be identified with myelography or in cross sectional imaging. Depending on the severity of the clinical signs, CT or MRI will be necessary in case an extruded disc needs to be removed.

AGE

10/27/07

INTERPRETED BY

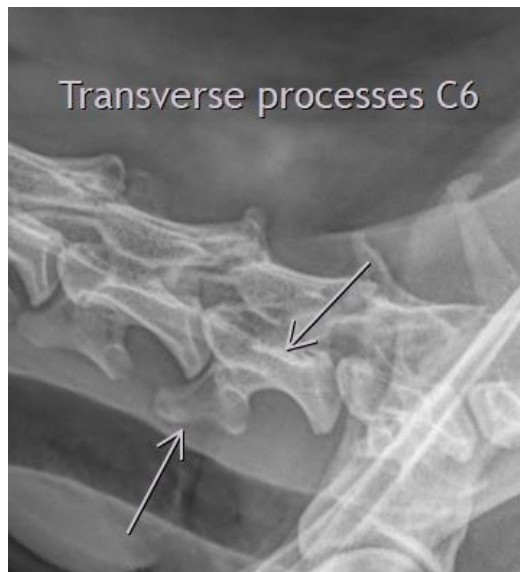
Heike Rudolf, DVM,
Dr. med. Vet.,
DipECVDI DVR

HOSPITAL NAME

Cottage Grove VC

REFERRING VET

Dr. Damewood



The information and recommendations provided are based on the images presented by the referring veterinarian/sonographer. No evaluation can be communicated regarding pathology that was not visible in the image/video clips provided.

INVOICE

23047 Thank you for this referral. If the clinical or image interpretation does not parallel your findings or if I can be of any further assistance please contact me.

DATE Heike Rudolf, DVM, Dr. med. vet., DipECVDI, DVR

6/23/23



PATIENT info@sonopath.com

Diesel Morelock

SPECIES

Canine

BREED

Min Pin

SEX

Neutered Male

AGE

10/27/07

INTERPRETED BY

Heike Rudorf, DVM,
Dr. med. Vet.,
DipECVDI DVR

HOSPITAL NAME

Cottage Grove VC

REFERRING VET

Dr. Damewood

INVOICE

23047

DATE

6/23/23