



**PATIENT PRESENTING CLINICAL SIGNS**

**PATIENT** Shnibbles Chmely **PRESENTING CLINICAL SIGNS** History: Reason for Visit: annual History: pet is here for annual/ pet will be going to behaviorist classes starting next friday- required vaccines- owner has no issues or concerns at home.

**SPECIES** Abnormal PE/Chem/CBC/UA Results: Hydration: N Mentation: QAR /Cautious EENT: N Oral Cavity: moderate to severe calculus Lymph Nodes: N Skin: N CV/Respiratory: N Abd/GI: N Uro/Perineum: N Musculoskeletal: N Neurological: N Diagnostic Testing Needed: 4 Dx Snap Test - Heartworm Positive  
**Canine**

**RADIOGRAPHIC STUDY OF THE THORAX**

**BREED** The body condition score is 5/9 with smooth alternating layers of fat and soft tissue opacity.

**Chihuahua** A calcified disc appears to be located in the intervertebral disc space L2/3 on the right lateral recumbent view only.

**SEX** The lungs are in contact with the thoracic boundaries and the tips are pointed. The lobar vessels are clearly visible to the tertiary branches. The bronchial tree is thin walled and tapers uniformly towards the periphery.  
**Neutered Male**

The cranial mediastinum is of physiological size and opacity. The trachea diverges from the thoracic vertebrae and dips at the carina.

**AGE** The cardiac silhouette occupies 75% of the chest height and 2.5 intercostal spaces. No chamber or outflow tract enlargement is evident.  
**4 Years 7 Months**

**RADIOGRAPHIC DIAGNOSIS**

- I can see no abnormalities.

**INTERPRETED BY**

Heike Rudolf, DVM,  
Dr. med. Vet.,  
DipECVDI DVR

**INTERPRETATION OF THE FINDINGS & FURTHER RECOMMENDATIONS**

The impression of disc calcification is probably due to divergence of the beam at the edge of the film. I can see no reason for the dog not to attend classes with a dog trainer.

**HOSPITAL NAME**

DPC Veterinary  
Hospital

**REFERRING VET**

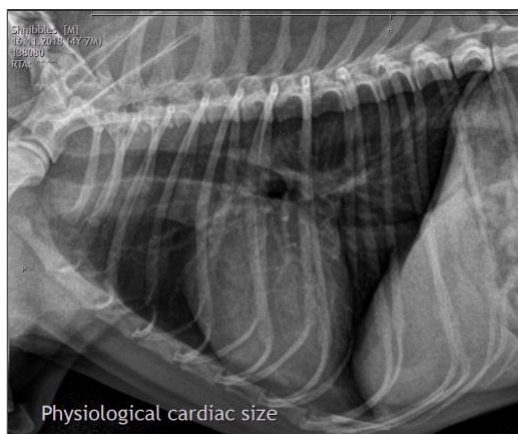
Dr. Weekes

**INVOICE**

23021

**DATE**

6/21/23





**PATIENT** The information and recommendations provided are based on the images presented by the referring veterinarian/sonographer. No evaluation can be communicated regarding pathology that was not visible in the image/video clips provided.

Shnibbles Chmely

Thank you for this referral. If the clinical or image interpretation does not parallel your findings or if I can be of any further assistance please contact me.

**SPECIES**

Canine **Heike Rudolf**, DVM, Dr. med. vet., DipECVDI, DVR  
info@sonopath.com

**BREED**

Chihuahua

**SEX**

Neutered Male

**AGE**

4 Years 7 Months

**INTERPRETED BY**

Heike Rudolf, DVM,  
Dr. med. Vet.,  
DipECVDI DVR

**HOSPITAL NAME**

DPC Veterinary  
Hospital

**REFERRING VET**

Dr. Weekes

**INVOICE**

23021

**DATE**

6/21/23