



PATIENT	PRESENTING CLINICAL SIGNS
Maverick Scarola	Inspiratory Strider, dx with enlarged heart by previous vet. On lasix Abnormal PE/Chem/CBC/UA Results: Inspiratory Strider
SPECIES	RADIOGRAPH OF THE THORAX
Canine	16.04.2022: non-DICOM images - RLR, 2x DV 16.04.2022: DICOM images - RLR, DV
BREED	RADIOGRAPHIC FINDINGS
English Bulldog	The body condition score is 8/9 with smooth alternating layers of fat and soft tissue opacity. Vertebrae T4- T7 are shortened and T7 is wedge shaped.
SEX	<u>Thorax</u>
MN	The lungs are in contact with the thoracic boundaries and the tips are pointed. The lobar vessels are clearly visible to the tertiary branches on the lateral view. On the dv the left sided vessels appear blurred.
AGE	The cranial mediastinum is of physiological size and opacity. The trachea diverges from the thoracic vertebrae and the carina is located at T5.
6 Years	The cardiac silhouette occupies 75% of the chest height and 3 intercostal spaces. No chamber or outflow tract enlargement is evident.
INTERPRETED BY	A large amount of air is present in the stomach.
Heike Rudolf, DVM, Dr. med. Vet., DipECVDDI DVR	RADIOGRAPHIC DIAGNOSIS
HOSPITAL NAME	<ul style="list-style-type: none"> • Interstitial pattern left side • Aerophagia • Congenital vertebral anomalies
Hamburg Veterinary Clinic	INTERPRETATION OF THE FINDINGS & FURTHER RECOMMENDATIONS
REFERRING VET	The interstitial lung pattern on the left is a non-specific finding and accentuated by the high body condition score.
Dr. DenHeyer	Due to the chest conformation the cardiac silhouette in bull dogs can appear subjectively large and if a VHS cannot be obtained due to vertebral anomalies it is difficult to compare cardiac size to normal dogs of the same breed. Thus, echocardiography is necessary if clinical signs or auscultation suggest cardiac disease. CT is recommended to assess nares, nasal turbinates and soft palate. Intermittent tracheal collapse may be present in cases of severe dyspnea.
INVOICE	
52489	
DATE	
6-17-22	



PATIENT

Maverick Scarola

SPECIES

Canine

BREED

English Bulldog

SEX

MN

AGE

6 Years

INTERPRETED BY

Heike Rudolf, DVM,
Dr. med. Vet.,
DipECVDI DVR

HOSPITAL NAME

Hamburg Veterinary
Clinic

REFERRING VET

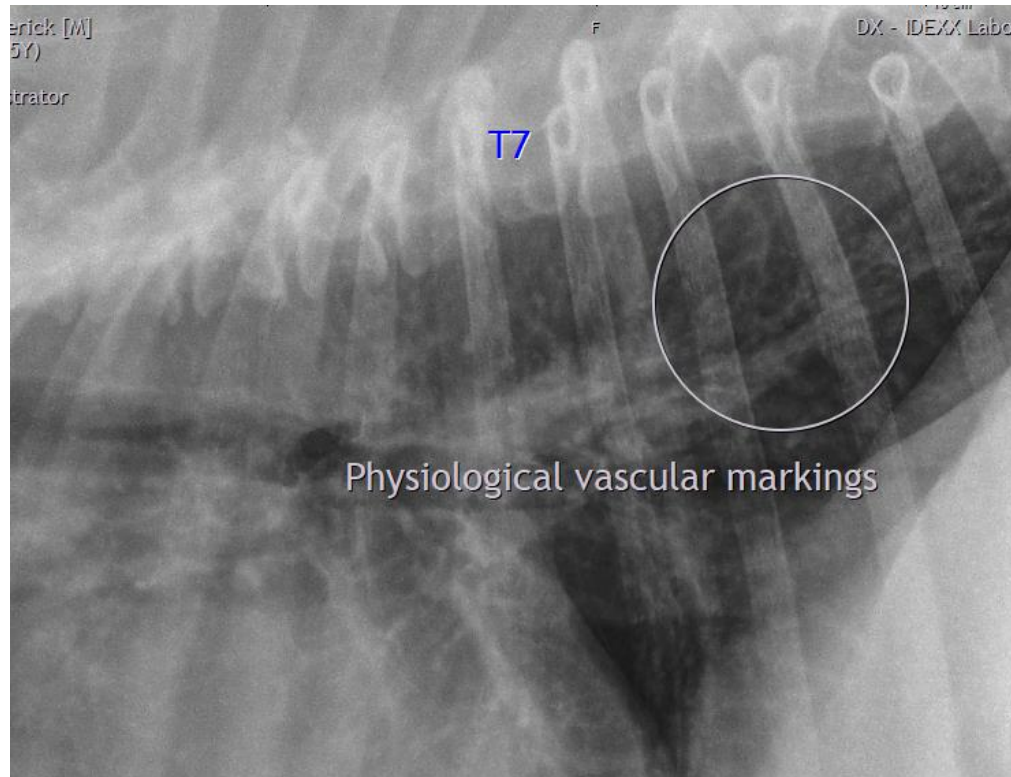
Dr. DenHeyer

INVOICE

52489

DATE

6-17-22



The information and recommendations provided are based on the images presented by the referring veterinarian/sonographer. No evaluation can be communicated regarding pathology that was not visible in the image/video clips provided.

Thank you for this referral. If the clinical or image interpretation does not parallel your findings or if I can be of any further assistance please contact me.

Heike Rudolf, DVM, Dr. med. vet., DipECVDI, DVR
Dr.H.Rudorf@gmail.com