



PATIENT PRESENTING CLINICAL SIGNS

PATIENT Marcus Valencia
SPECIES Canine
SEX Neutered Male
AGE 14 Years

History: Pt's history is less active, lethargic, not wanting to ambulate and having semi-formed stools for the last few weeks. Not following owner around the house, which is his norm. B/w - mildly elevated ALT at 278 IU/L and ALP at 141 IU/L. Everything else on b/w - wnl's. Valley Fever Titer- negative. Fecal PCR- undetected. No coughing noted. Pt was on rimadyl, currently holding d/t elevated liver enzymes and is just on gabapentin. No murmur on PE. Heart subjectively on V/D view looks rounded??--> concerning at all?

RADIOGRAPHIC STUDY OF THE THORAX

BREED Lab Retriever Mix
SEX Neutered Male
AGE 14 Years

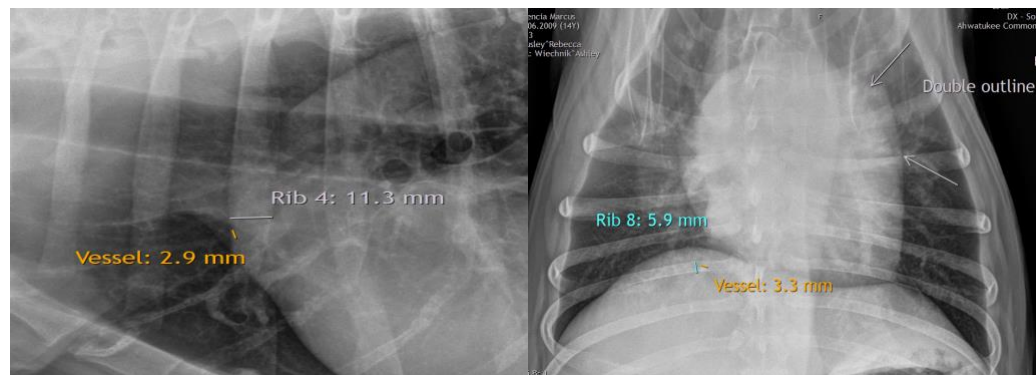
The body condition score is 6/9 with smooth alternating layers of fat and soft tissue opacity. Thoracic ventral spondylosis is present. The degree of pulmonary expansion on both lateral views is fair. The lungs are in contact with the thoracic boundaries and the tips are pointed. The lobar vessels are visible to the tertiary branches but appear small. The bronchial tree is thin walled and tapers uniformly towards the periphery. The cranial mediastinum is of physiological size and opacity. The trachea diverges markedly from the thoracic vertebrae and the carina is located at T5/6. The cardiac silhouette occupies 70% of the chest height and 2.5 intercostal spaces. A mild double outline is present at 2 o'clock.

RADIOGRAPHIC DIAGNOSIS

- Hypovolemia
- Microcardia, mild

INTERPRETATION OF THE FINDINGS & FURTHER RECOMMENDATIONS

The changes are suggestive of hypovolemia. The most likely reasons are dehydration, Addison's disease or bleeding. Abdominal ultrasound is recommended to rule out retroperitoneal hemorrhage, tumor in one or more of the abdominal organs and gastric or duodenal ulceration. The double outline in the region of the main pulmonary artery is probably due to the overall reduction in cardiac size and the resulting upright position of the heart.



INTERPRETED BY

Heike Rudolf, DVM,
 Dr. med. Vet.,
 DipECVDI DVR

HOSPITAL NAME

Ahwatukee Commons
 VH

REFERRING VET

Becky R. Housley,
 DVM

INVOICE

22968

DATE

6/16/23



PATIENT

Marcus Valencia

The information and recommendations provided are based on the images presented by the referring veterinarian/sonographer. No evaluation can be communicated regarding pathology that was not visible in the image/video clips provided.

SPECIES

Canine

Thank you for this referral. If the clinical or image interpretation does not parallel your findings or if I can be of any further assistance please contact me.

Heike Rudorf, DVM, Dr. med. vet., DipECVDI, DVR
info@sonopath.com

BREED

Lab Retriever Mix

SEX

Neutered Male

AGE

14 Years

INTERPRETED BY

Heike Rudorf, DVM,
Dr. med. Vet.,
DipECVDI DVR

HOSPITAL NAME

Ahwatukee Commons
VH

REFERRING VET

Becky R. Housley,
DVM

INVOICE

22968

DATE

6/16/23