



**PATIENT PRESENTING CLINICAL SIGNS**

Lilly Healy History: Acute lameness. Started about a month ago. Uses leg intermittently. Painful to the touch

**RADIOGRAPHIC STUDY OF THE STIFLES**

**SPECIES**

Rabbit

A soft tissue swelling surrounds the proximal left tibia/fibula and is most prominent on the lateral aspect.

**BREED**

California

The proximal fibula has been destroyed and some spicules remain in the region of the former cortex. An increased lucency of the lateral femoral condyle and the intercondylar eminence of the tibia are present as well. The lateral tibial cortex is thin: approx. 1.3cm distal to the tibial joint surface it is disrupted and appears medially displaced.

**RADIOGRAPHIC DIAGNOSIS**

**SEX**

Spayed Female

- Soft tissue swelling
- Soft tissue within the stifle joint
- Bone destruction: tibia, fibula, lateral femoral condyle
- Possible pathological fracture lateral tibia

**AGE**

10

**INTERPRETATION OF THE FINDINGS & FURTHER RECOMMENDATIONS**

The changes are highly suggestive of a septic arthritis which began on the lateral aspect. Synovial cell sarcoma or fibrosarcoma are differential diagnoses but are unlikely in a rabbit. Samples should be obtained from the joint and from the region of the former fibula head and submitted for bacteriological and histological examination. After that antibiotic treatment can be initiated and should be combined with pain killers. Prognosis, however, is poor due to the bone destruction and possible pathological fracture.

**INTERPRETED BY**

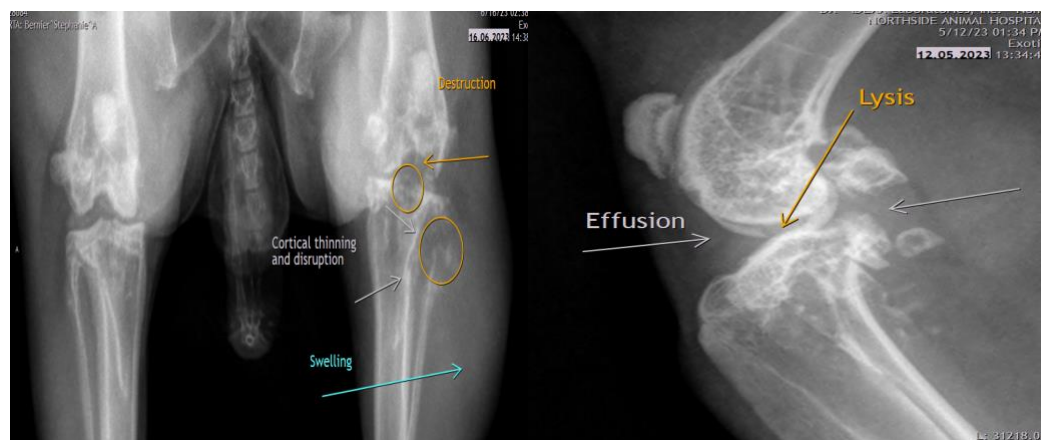
Heike Rudorf, DVM,  
Dr. med. Vet.,  
DipECVDI DVR

**HOSPITAL NAME**

RB Northside AH

**REFERRING VET**

Dr. Leslie Agulnick



**INVOICE**

22967

The information and recommendations provided are based on the images presented by the referring veterinarian/sonographer. No evaluation can be communicated regarding pathology that was not visible in the image/video clips provided.

**DATE**

6/16/23



**PATIENT** Thank you for this referral. If the clinical or image interpretation does not parallel your findings or if I can be of any further assistance please contact me.

Lilly Healy

**Heike Rudolf**, DVM, Dr. med. vet., DipECVDI, DVR  
info@sonopath.com

**SPECIES**

Rabbit

**BREED**

California

**SEX**

Spayed Female

**AGE**

10

**INTERPRETED BY**

Heike Rudolf, DVM,  
Dr. med. Vet.,  
DipECVDI DVR

**HOSPITAL NAME**

RB Northside AH

**REFERRING VET**

Dr. Leslie Agulnick

**INVOICE**

22967

**DATE**

6/16/23