



PATIENT PRESENTING CLINICAL SIGNS

Daisy Duke History: Hx mitral valve insufficiency stage B1 diagnosed with US one year ago
 Odencrantz Abnormal PE/Chem/CBC/UA Results: Heart murmur grade 3/6

RADIOGRAPHIC STUDY OF THE THORAX

SPECIES

Canine The body condition score is 6/9 with smooth alternating layers of fat and soft tissue opacity.
 Spondylosis is present on the endplates of L1 and L2.

BREED

CKCS The lungs are in contact with the thoracic boundaries and the tips are pointed. The lobar vessels are clearly visible to the tertiary branches and are of physiological size. The bronchial tree is thin walled and tapers uniformly towards the periphery.

SEX

The cranial mediastinum is of physiological size and opacity. The trachea diverges from the thoracic vertebrae and dips at the carina.

Spayed Female

The cardiac silhouette occupies 75% of the chest height and 3 intercostal spaces (VHS 11). Both main stem bronchi are slightly displaced laterally, resulting a semi-circular path. The edges of the cardiac silhouette are smooth.

AGE

N/A

RADIOGRAPHIC DIAGNOSIS

- Mild left atrial (LA) enlargement

INTERPRETED BY

INTERPRETATION OF THE FINDINGS & FURTHER RECOMMENDATIONS

Heike Rudolf, DVM,
 Dr. med. Vet.,
 DipECVDDI DVR

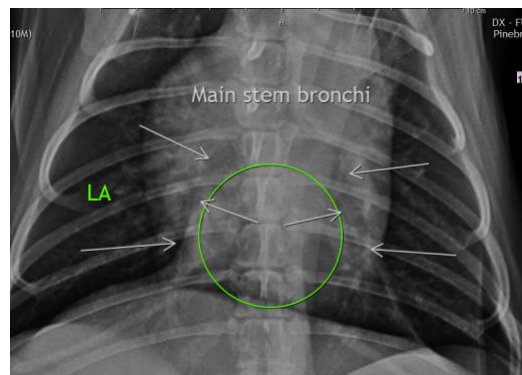
The shape of the main stem bronchi on the DV view is suggestive of a mild left atrial enlargement though a lateral displacement of the left auricle is not obvious. Thus, mild mitral regurgitation may be present, but echocardiography is needed to compare the changes detected a year ago.

HOSPITAL NAME

Pinebrook AH

REFERRING VET

Dr. Britt Dubil



INVOICE

16111

DATE

6/16/22



PATIENT

Daisy Duke
Odenchantz

The information and recommendations provided are based on the images presented by the referring veterinarian/sonographer. No evaluation can be communicated regarding pathology that was not visible in the image/video clips provided.

Thank you for this referral. If the clinical or image interpretation does not parallel your findings or if I can be of any further assistance please contact me.

SPECIES

Canine

Heike Rudolf, DVM, Dr. med. vet., DipECVDI, DVR
dr.h.rudorf@gmail.com

BREED

CKCS

SEX

Spayed Female

AGE

N/A

INTERPRETED BY

Heike Rudolf, DVM,
Dr. med. Vet.,
DipECVDI DVR

HOSPITAL NAME

Pinebrook AH

REFERRING VET

Dr. Britt Dubil

INVOICE

16111

DATE

6/16/22