



**PATIENT PRESENTING CLINICAL SIGNS**

Sophie Robert Presented today for possible broken leg on the front right. Noticed 2 days ago. She has decreased energy, appetite, drinking and urination. She has increased breathing.

**SPECIES** Abnormal PE/Chem/CBC/UA Results: GRADE 4/5 RIGHT FRONT LAME SWELLING AND PAIN IN DISTAL RADIUS, POSSIBLY IN THE CARPUS AS WELL. MILD TARTAR ONLY

Canine **RADIOGRAPH OF THE RIGHT FORE PAW**

1x lateral, 1x flexed carpus lateral, 1x DP, 2x DP oblique

**BREED RADIOGRAPHIC FINDINGS**

Australian Shepherd Mix  
 A moderate soft tissue swelling surrounds the carpal joints and is especially pronounced dorsal to the flexed carpus in the region of the extensor tendons. The fat opacity caudal to the distal antebrachium is tear drop shaped and interrupted by soft tissue layers. A small, mineral opacity is evident lateral to the cortex of P1 digit 4 and lateral to the distal interphalangeal joint space of digit 5; on the lateral view one such opacity appears to be located in the pad of one of the shorter digits (2 or 5).

**SEX** FS

**AGE** 6 Years, 1 Month  
 Smooth new bone spurs are evident on the dorso-proximal and medial aspect of one metacarpus (MC) and the lateral aspects of MC 1 of the first MC-phalangeal joint. A small amount of new bone formation with a slightly undulating border is located on the dorsal aspect of the radio-carpal bone and the cranial aspect of the distal radius. Smooth new bone is located on the distal accessory carpal bone. A 0.2 x 0.1cm bone opacity appears to be present distal to the slightly irregular palmaro-distal surface of the radio-carpal bone but is not visible on either of the two lateral views.

**INTERPRETED BY** Heike Rudolf, DVM, Dr. med. Vet., DipECVDDI DVR  
 The bones are well mineralized, have a normal trabecular structure and continuous surfaces. Cortical-medullary development and differentiation of the long bones are present; the metacarpal show a slightly cloudy increased medullary opacity.

**HOSPITAL NAME RADIOGRAPHIC DIAGNOSIS**

Elizabeth Animal Hospital  
 Carpus:  
 • Soft tissue swelling  
 • Arthrosis, esp. medial aspect  
 • Possible small fragment palmar aspect proximal intercarpal joint

**REFERRING VET** Leon Anderson, DVM  
 Paw:  
 • Possible foreign body pad of one toe

**INVOICE INTERPRETATION OF THE FINDINGS & FURTHER RECOMMENDATIONS**

52397 I can see no fracture line. However, a follow up DP view should be obtained in 10 days to allow osteoclastic activity to widen a possible hairline fissure which may not be visible on the current radiographs. The carpal changes are most likely the result of a previous single or a repetitive trauma (e.g. due to a sport such as agility). The swelling most likely represents fibrosis or a mixture of fibrosis and fluid. Ultrasound is recommended to assess the extensor tendons for integrity and the swelling for the presence of fluid. The pads should be examined ultrasonographically as well to allow identification of a potential foreign object (best seen when

**DATE**

6-10-22



**PATIENT**

Sophie Robert

surrounded by fluid). The bone fragment is probably attached to the synovia and may not be causing clinical signs. The slightly cloudy metacarpal opacity most likely represents a variation of normal anatomy, but manual pressure should be applied to rule out panosteitis.

**SPECIES**

Canine

**BREED**

Australian Shepherd  
Mix

**SEX**

FS

**AGE**

6 Years, 1 Month

**INTERPRETED BY**

Heike Rudorf, DVM,  
Dr. med. Vet.,  
DipECVDI DVR

**HOSPITAL NAME**

Elizabeth Animal  
Hospital

**REFERRING VET**

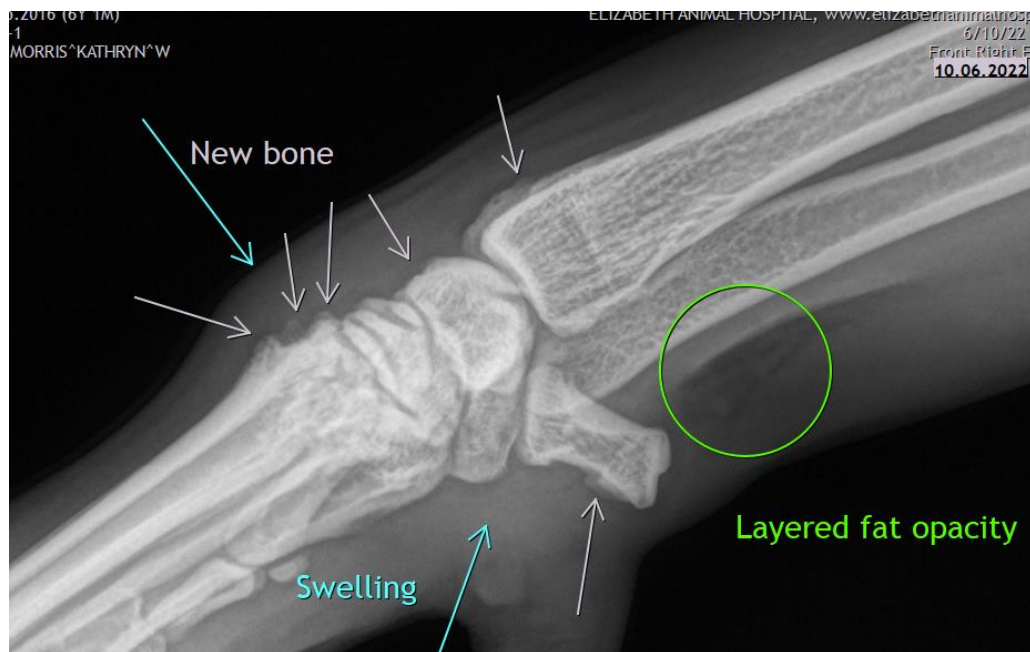
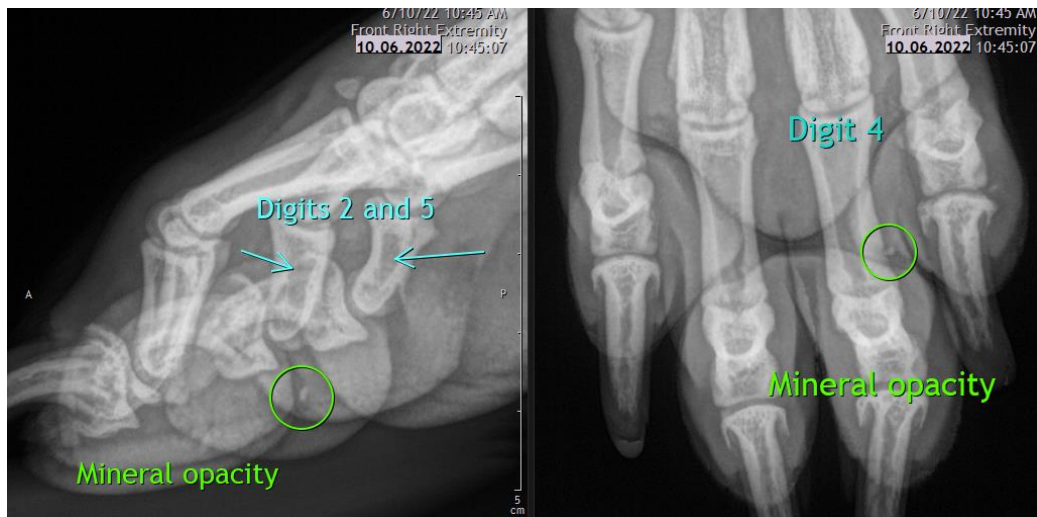
Leon Anderson, DVM

**INVOICE**

52397

**DATE**

6-10-22





**PATIENT**

Sophie Robert

**SPECIES**

Canine

**BREED**

Australian Shepherd  
Mix

**SEX**

FS

**AGE**

6 Years, 1 Month

**INTERPRETED BY**

Heike Rudolf, DVM,  
Dr. med. Vet.,  
DipECVDI DVR

**HOSPITAL NAME**

Elizabeth Animal  
Hospital

**REFERRING VET**

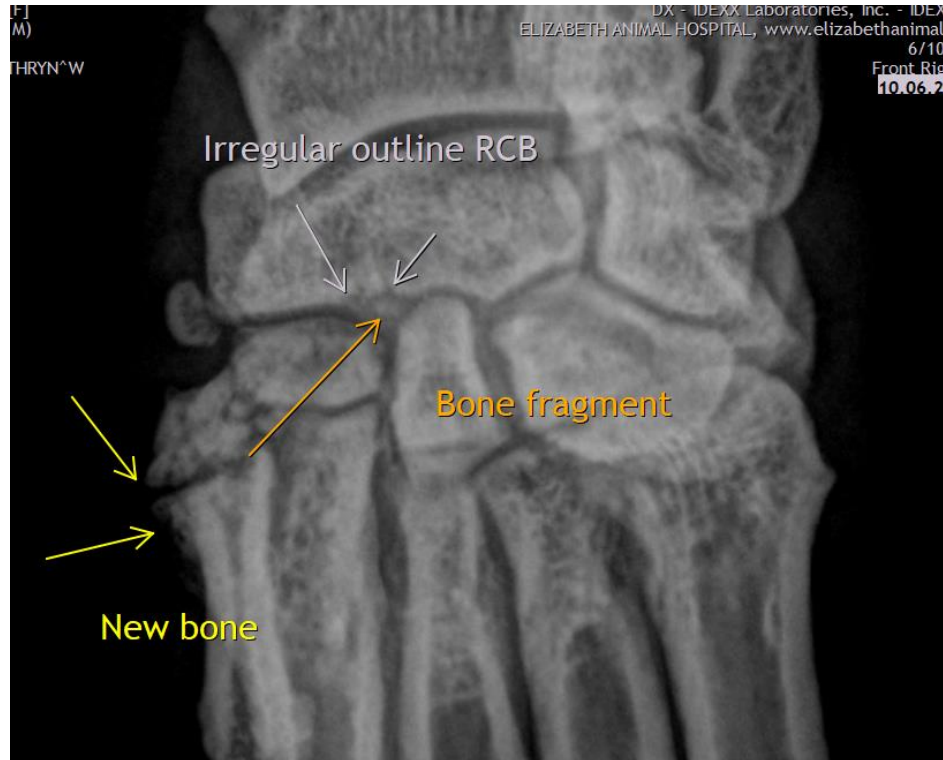
Leon Anderson, DVM

**INVOICE**

52397

**DATE**

6-10-22



The information and recommendations provided are based on the images presented by the referring veterinarian/sonographer. No evaluation can be communicated regarding pathology that was not visible in the image/video clips provided.

Thank you for this referral. If the clinical or image interpretation does not parallel your findings or if I can be of any further assistance please contact me.

**Heike Rudolf**, DVM, Dr. med. vet., DipECVDI, DVR  
Dr.H.Rudorf@gmail.com