



PATIENT

Bullitt Lynn

SPECIES

Canine

BREED

American Staffordshire
Terrier

SEX

MN

AGE

8Y, 8M, 22D

WEIGHT

35kg

INTERPRETED BY

Heike Rudolf, DVM, Dr.
med. Vet., DipECVDI
DVR

IMAGING PERFORMED BY

AMC/AS

HOSPITAL NAME

Green Dog Dental and
Wellness

REFERRING VET

Dr. Scott

INVOICE

75226

DATE

6-1-26

PRESENTING CLINICAL SIGNS

History of chronic, intermittent forelimb lameness and difficulty ascending stairs for several months.

RADIOGRAPHS OF SHOULDERS AND ELBOWS

R/L lateral and VD, totaling 8 radiographs provided for interpretation.

RADIOGRAPHIC FINDINGS

On the lateral shoulder views the muscle mass caudal to the left distal humerus appears slightly reduced (R=2cm, L=1.4cm) and the caudal fascial plains are clearly outlined by fat.

The bones are well mineralized, have a normal trabecular structure and smooth, continuous surfaces. Cortico-medullary development and differentiation of the long bones is symmetrical.

Shoulders: the joints appear congruent with even subchondral and periosteal surfaces. The bony structure cranial to the greater tubercle most likely represents a clavicular remanent.

Elbows: the joint appears congruent with even subchondral and periosteal surfaces. The medial coronoid process is sharply delineated.

RADIOGRAPHIC DIAGNOSIS

Left:

- Muscle atrophy caudal humerus

INTERPRETATION OF THE FINDINGS & FURTHER RECOMMENDATIONS

It is difficult to accurately assess the muscle size radiographically. I suggest using a tape measure to confirm/refute the suspicion. True muscle atrophy in the absence of other diseases can be due to brachial plexus neuropathies and requires cross sectional imaging. Flexor myositis and distal tendinitis can be ruled out during the same examination. Difficulties in climbing stairs could also be related to spinal cord compression, e.g., disc disease. The results of the neurological examination may lead to cross sectional imaging.



PATIENT

Bullitt Lynn

SPECIES

Canine

BREED

American Staffordshire
Terrier

SEX

MN

AGE

8Y, 8M, 22D

WEIGHT

35kg

INTERPRETED BY

Heike Rudolf, DVM, Dr.
med. Vet., DipECVDI
DVR

IMAGING PERFORMED BY

AMC/AS

HOSPITAL NAME

Green Dog Dental and
Wellness

REFERRING VET

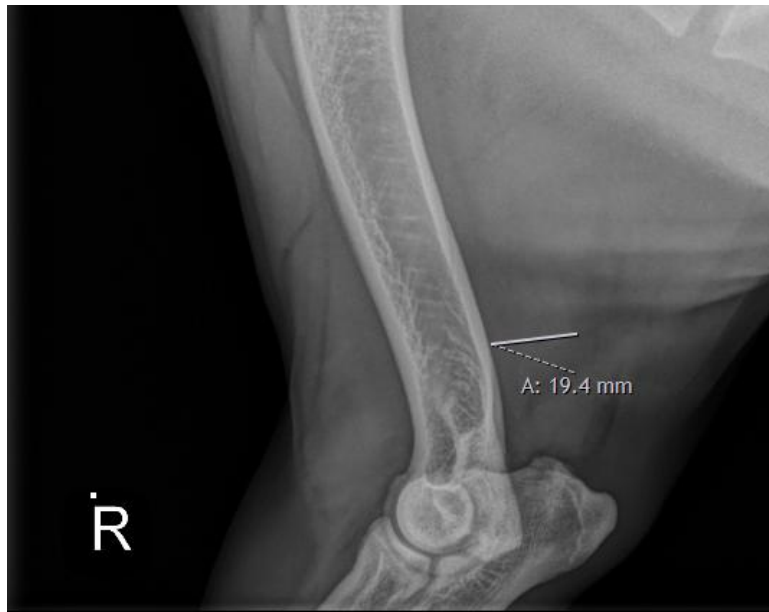
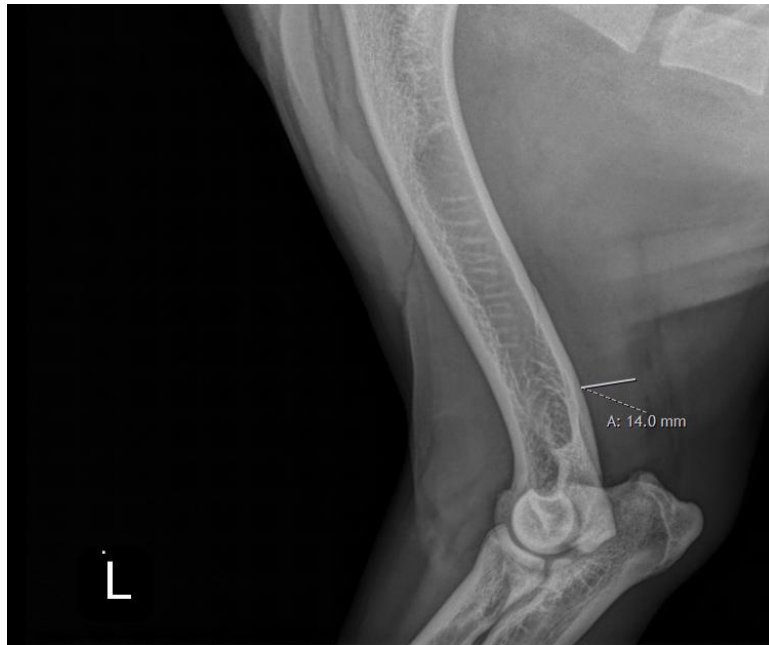
Dr. Scott

INVOICE

75226

DATE

6-1-26



The information and recommendations provided are based on the images presented by the referring veterinarian/sonographer. No evaluation can be communicated regarding pathology that was not visible in the image/video clips provided.

Thank you for this referral. If the clinical or image interpretation does not parallel your findings or if I can be of any further assistance, please contact me.

Heike Rudolf, DVM, Dr. med. vet., DipECVDI, DVR
info@sonopath.com