

## PATIENT

Rhea St. Clair

## SPECIES

Feline

## BREED

Maine Coon Mix

## SEX

Spayed Female

## AGE

10 Months

## WEIGHT

8 lbs

## INTERPRETED BY

Heike Rudolf, DVM, Dr.  
med. Vet., DipECVDF  
DVR

## IMAGING PERFORMED BY

Mallory Frois

## HOSPITAL NAME

The Pet Hospital of  
Stratford

## REFERRING VET

Dr. David

## INVOICE

15985

## DATE

05/06/26

## PRESENTING CLINICAL SIGNS

O noted noise when eating food, sounds like grinding or clicking. Per o favors left side of mouth. Does not happen all the time. No v/d/c/s.

Abnormal PE/Chem/CBC/UA Results: jaw palpates normal, no noise heard when opening and closing mouth. No pain. teeth normal.

## RADIOGRAPHIC STUDY OF THE HEAD

R/L lateral and VD, totaling four radiographs provided for interpretation.

06.05.2026

## RADIOGRAPHIC FINDINGS

The surrounding soft tissue structures appear symmetric and physiological.

The bony structures appear unremarkable; the dentition is symmetrical.

The temporo-mandibular joints (TMJs) are congruent. In left lateral recumbency a small, rhomboid bone structure is located ventral to the highlighted retro-articular process.

Both nares contain air. Maxilla- and ethmoid turbinates are surrounded by air.

Bullae and external ear canals are filled with air. The walls are symmetrical and physiological.

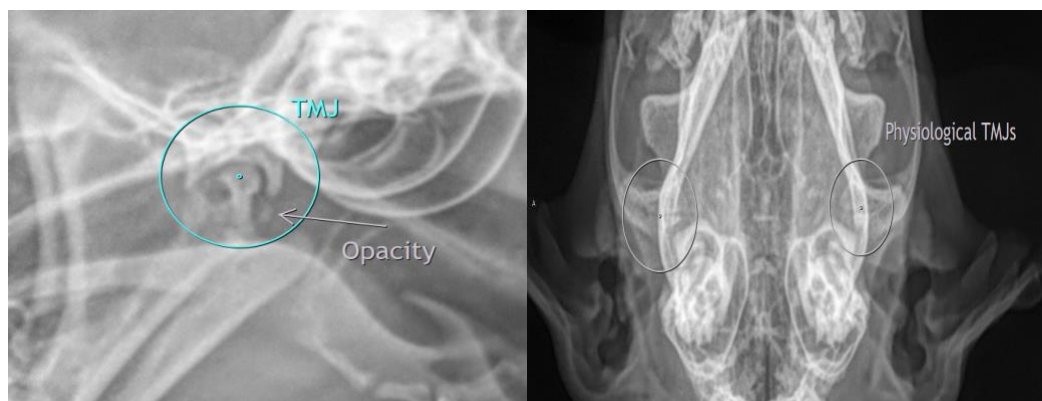
Naso- and laryngopharynx are filled with air.

## RADIOGRAPHIC DIAGNOSIS

- Mineral opacity ventral to one retro-articular process

## INTERPRETATION OF THE FINDINGS & FURTHER RECOMMENDATIONS

The retroarticular processes appear physiologically developed and the "fragment" is located relatively far ventrally to be present within the joint capsule. It is thus likely a superimposed shadow. However, should the clinical signs persist, a CT examination is recommended with the mouth slightly more open than for the radiographs. Alternatively, oblique lateral views of each individual TMJ can be obtained.



The information and recommendations provided are based on the images presented by the referring veterinarian/sonographer. No evaluation can be communicated regarding pathology that was not visible in the image/video clips provided.



**PATIENT**

Rhea St. Clair

**SPECIES**

Feline

**BREED**

Maine Coon Mix

**SEX**

Spayed Female

**AGE**

10 Months

**WEIGHT**

8 lbs

**INTERPRETED BY**

Heike Rudolf, DVM, Dr.  
med. Vet., DipECVDI  
DVR

**IMAGING  
PERFORMED BY**

Mallory Frois

**HOSPITAL NAME**

The Pet Hospital of  
Stratford

**REFERRING VET**

Dr. David

**INVOICE**

15985

**DATE**

05/06/26

Thank you for this referral. If the clinical or image interpretation does not parallel your findings or if I can be of any further assistance, please contact me.

**Heike Rudolf, DVM, Dr. med. vet., DipECVDI, DVR**  
[info@sonopath.com](mailto:info@sonopath.com)