

PATIENT

Rascal Keator

SPECIES

Feline

BREED

DSH

SEX

Neutered Male

AGE

10 Years

WEIGHT

18.7 lbs

INTERPRETED BY

Heike Rudolf, DVM, Dr.
med. Vet., DipECVDD
DVR

IMAGING PERFORMED BY

Jennifer & Chelsea

HOSPITAL NAME

Northvale Veterinary
Clinic

REFERRING VET

Dr. Stefanie Simon

INVOICE

15984

DATE

05/06/26

PRESENTING CLINICAL SIGNS

Coughing and sneezing for the past few days.

Abnormal PE/Chem/CBC/UA Results: Pending.

RADIOGRAPHIC STUDY OF THE THORAX

R/L lateral and VD are provided, totaling 3 radiographs for interpretation.

5/6/26

RADIOGRAPHIC FINDINGS

The body condition score is 7-8/9 with a large amount of intraabdominal fat.

The bony structures appear physiological.

The cranial mediastinum is of physiologic size and opacity. The trachea diverges from the thoracic vertebrae and the carina is located level with T5/6. A small amount of air outlines the cranial thoracic esophagus in left lateral recumbency.

The cardiac silhouette occupies 75% of the chest height and 2 intercostal spaces. A chamber or outflow tract enlargement is not obvious.

The degree of pulmonary expansion is fair. The vascular margins are blurred. Tramlines and doughnuts are evident in the caudo-dorsal lung fields.

RADIOGRAPHIC DIAGNOSIS

- Broncho-interstitial pattern
- Obesity

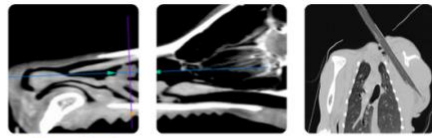
INTERPRETATION OF THE FINDINGS & FURTHER RECOMMENDATIONS

An interstitial lung pattern is a non-specific finding and accentuated by the obesity and only fair expansion of the lung field. Possible differential diagnoses for a true infiltrate include:

- Infection (viral, bacterial, fungal, parasitic e.g., aelurostrongylus)
- Inflammation (allergic pneumonitis, eosinophilic bronchopneumopathy)
- Edema
- Diffuse hemorrhage
- Early idiopathic fibrosis
- Tumor (e.g., lymphoma)

In combination, sneezing and coughing could be due to environmental allergies.

Fecal samples should be obtained to rule out parasites. Bronchitis can be present without or only little radiographic evidence and thus bronchoscopy with broncho-alveolar lavage is recommended; samples should be submitted for bacteriological and cytological examination. Obesity is known to worsen clinical signs of cough and impair lung function; weight control is strongly recommended.



PATIENT

Rascal Keator

SPECIES

Feline

BREED

DSH

SEX

Neutered Male

AGE

10 Years

WEIGHT

18.7 lbs

INTERPRETED BY

Heike Rudolf, DVM, Dr.
med. Vet., DipECVDI
DVR

IMAGING PERFORMED BY

Jennifer & Chelsea

HOSPITAL NAME

Northvale Veterinary
Clinic

REFERRING VET

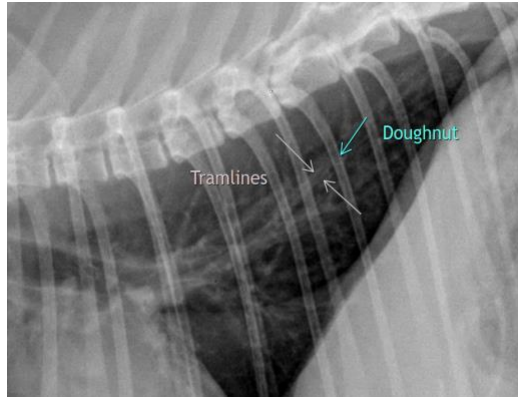
Dr. Stefanie Simon

INVOICE

15984

DATE

05/06/26



The information and recommendations provided are based on the images presented by the referring veterinarian/sonographer. No evaluation can be communicated regarding pathology that was not visible in the image/video clips provided.

Thank you for this referral. If the clinical or image interpretation does not parallel your findings or if I can be of any further assistance, please contact me.

Heike Rudolf, DVM, Dr. med. vet., DipECVDI, DVR
info@sonopath.com