



PATIENT

Gigi Lopez

SPECIES

Canine

BREED

Yorkie

SEX

SF

AGE

5Y

WEIGHT

10.8lbs

INTERPRETED BY

Heike Rudolf, DVM, Dr.
med. Vet., DipECVDI
DVR

IMAGING PERFORMED BY

GC

HOSPITAL NAME

The Pet Hospital of
Stratford

REFERRING VET

Dr. Claudia Giuliani, DVM

INVOICE

74920

DATE

5-6-26

PRESENTING CLINICAL SIGNS

Gigi presents for urinating in small amounts - no blood seen. Started a few days ago. No concerns otherwise.

RADIOGRAPHS OF THE ABDOMEN

R/L lateral and VD, totaling 3 radiographs provided for interpretation.

RADIOGRAPHIC FINDINGS

The body condition score is 6/9 with smooth, alternating layers of fat and soft tissue opacity.

The bony structures appear physiological.

The abdominal organs are surrounded by fat; the abdominal wall is intact.

The liver is located within the costal arch.

The spleen appears physiological.

The gastric axis is slightly cranially rotated. Distribution and size of the small intestinal loops appear physiological. Colon and rectum contain some fecal matter.

The left renal shadow has a physiological size, shape and opacity; the right is obscured by intestinal loops. The bladder shadow is small and contains multiple small to medium sized mineral opacities in its center.

The sublumbar region appears physiological.

RADIOGRAPHIC DIAGNOSIS

- Cystic calculi

INTERPRETATION OF THE FINDINGS & FURTHER RECOMMENDATIONS

Abdominal ultrasound is recommended to check kidneys, ureters and urethra for small calculi. A sterile urine sample can be obtained at the same time for bacteriology and to identify the type of calculus. Depending on the type of stone, a therapeutic diet to dissolve the stones may suffice (struvite). Flushing the stones out with urohydropropulsion may be another option; this way an entire stone can be submitted for analysis.



PATIENT

Gigi Lopez

SPECIES

Canine

BREED

Yorkie

SEX

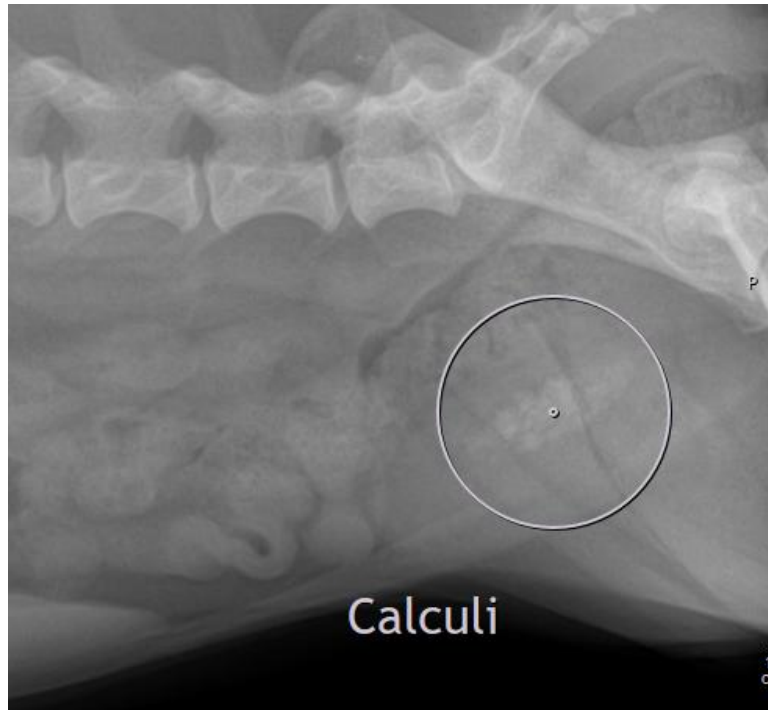
SF

AGE

5Y

WEIGHT

10.8lbs



INTERPRETED BY

Heike Rudolf, DVM, Dr.
med. Vet., DipECVDI
DVR

IMAGING PERFORMED BY

GC

HOSPITAL NAME

The Pet Hospital of
Stratford

REFERRING VET

Dr. Claudia Giuliani, DVM

INVOICE

74920

DATE

5-6-26

The information and recommendations provided are based on the images presented by the referring veterinarian/sonographer. No evaluation can be communicated regarding pathology that was not visible in the image/video clips provided.

Thank you for this referral. If the clinical or image interpretation does not parallel your findings or if I can be of any further assistance, please contact me.

Heike Rudolf, DVM, Dr. med. vet., DipECVDI, DVR
info@sonopath.com