



PATIENT PRESENTING CLINICAL SIGNS

Wally Bauder History: Progressive lameness past 2 weeks. Painful in front legs. Could not examine awake

SPECIES

Canine Skeletal immaturity compatible with the given age is noted.
Mild soft tissue swelling surrounds the distal antebrachium.

BREED

Tibetan Mastiff

The shoulder joints appear congruent with even subchondral bone surfaces. A small amount of periosteal new bone formation is located on the right caudal humeral diaphysis.

SEX

Male

Thickening of the proximal and distal radial diaphyses as well as distal ulnar diaphyses is accompanied by sclerosis. A lucent line is located proximal to the distal radial and ulnar physes. Paraperiosteal new bone formation is present.

RADIOGRAPHIC DIAGNOSIS

- Metaphyseal osteopathy

AGE

24 Weeks

INTERPRETATION OF THE FINDINGS & FURTHER RECOMMENDATIONS

Metaphyseal osteopathy, (also known as hypertrophic osteodystrophy) is a syndrome seen in young medium, large and giant breeds of dogs. Age of onset ranges between 7 weeks and 8 months, and the highest incidence is reported for dogs between 3 and 4 months of age. Fever, anorexia, and depression are present in many cases. The disease is self-limiting and symptomatic treatment e.g. iv fluids, analgesics, NSAIDs is recommended. A less common, peracute presentation with severe systemic illness may warrant immunosuppressive corticosteroid therapy. Autoinflammatory disorder may play a role.

INTERPRETED BY

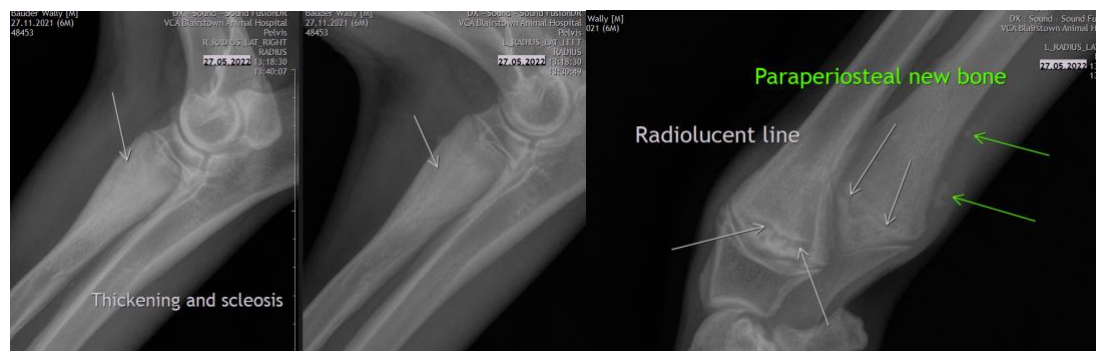
Heike Rudorf, DVM,
Dr. med. Vet.,
DipECVDI DVR

HOSPITAL NAME

Blairstown AH

REFERRING VET

Dr. Clegg



INVOICE

15768

The information and recommendations provided are based on the images presented by the referring veterinarian/sonographer. No evaluation can be communicated regarding pathology that was not visible in the image/video clips provided.

DATE

5/27/22



PATIENT

Thank you for this referral. If the clinical or image interpretation does not parallel your findings or if I can be of any further assistance please contact me.

Wally Bauder

Heike Rudorf, DVM, Dr. med. vet., DipECVDI, DVR
dr.h.rudorf@gmail.com

SPECIES

Canine

BREED

Tibetan Mastiff

SEX

Male

AGE

24 Weeks

INTERPRETED BY

Heike Rudorf, DVM,
Dr. med. Vet.,
DipECVDI DVR

HOSPITAL NAME

Blairstown AH

REFERRING VET

Dr. Clegg

INVOICE

15768

DATE

5/27/22