



PATIENT PRESENTING CLINICAL SIGNS

Toby Patel History: limping on right hind leg no history of injury or trauma

RADIOGRAPHIC STUDY OF THE PELVIS AND STIFLES

SPECIES

Feline

The skin surfaces are smooth, and the muscles appear to be symmetrically developed.

All bones are well mineralized, have a normal trabecular structure and a smooth surface. Cortical-medullary development and differentiation of the long bones are physiological.

BREED

DSH

The centre of both femoral heads is located medial to the respective dorsal acetabular edge. Both hip joints appear congruent with even subchondral bone surfaces. A spur of new bone (NB) is located on the right effective cranial acetabular edge.

SEX

Neutered Male

RADIOGRAPHIC DIAGNOSIS

- Mild OA right hip joint

INTERPRETATION OF THE FINDINGS & FURTHER RECOMMENDATIONS

AGE

7 Years

The small bone spur could be the result of joint instability which may cause an alternation of arthritis and arthrosis. Alternatively, a soft tissue injury (e.g. myositis, tendinitis) may be present. Should the clinical signs not respond to conservative management or progress, contrast CT or MRI is recommended.

INTERPRETED BY

Heike Rudorf, DVM,
Dr. med. Vet.,
DipECVDI DVR

TECHNICAL COMMENTS

Non-DICOM images were submitted. The transformation from DICOM to other formats reduces the image quality and only allows limited manipulation of the image. More subtle lesions can thus easily be missed. For the best possible imaging reports, I suggest submitting DICOM images in the future.

HOSPITAL NAME

The Collegeway AH

REFERRING VET

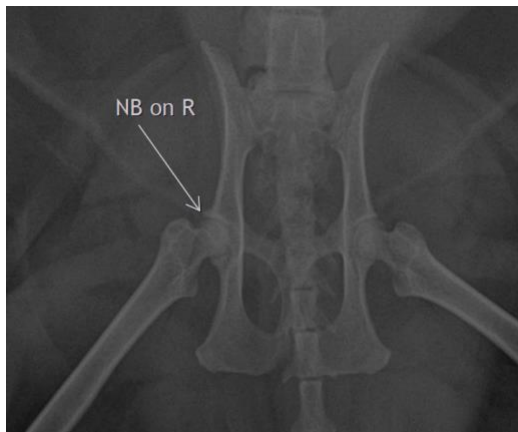
Dr. Ehab Hannah

INVOICE

15766

DATE

5/27/22





PATIENT The information and recommendations provided are based on the images presented by the referring veterinarian/sonographer. No evaluation can be communicated regarding pathology that was not visible in the image/video clips provided.

Toby Patel

Thank you for this referral. If the clinical or image interpretation does not parallel your findings or if I can be of any further assistance please contact me.

SPECIES

Feline **Heike Rudolf**, DVM, Dr. med. vet., DipECVDI, DVR
dr.h.rudorf@gmail.com

BREED

DSH

SEX

Neutered Male

AGE

7 Years

INTERPRETED BY

Heike Rudolf, DVM,
Dr. med. Vet.,
DipECVDI DVR

HOSPITAL NAME

The Collegeway AH

REFERRING VET

Dr. Ehab Hannah

INVOICE

15766

DATE

5/27/22