



PATIENT PRESENTING CLINICAL SIGNS

Friday Pickell History: Persistent loose stools. Hyporexia for last 2 days. Rapid weight loss over the last 2-3 weeks
 Abnormal PE/Chem/CBC/UA Results: Mildly prolonged skin tent, generalized muscle wasting, abd palpation did not reveal any obvious abnormalities.

SPECIES RADIOGRAPHIC STUDY OF THE ABDOMEN

Feline The body condition score is 3-4/9.

BREED The bony structures are within normal limits.

DSH The abdominal detail is poor and the abdominal wall is tucked up.

SEX The stomach contains a small amount of air in the fundus. Distension of small intestinal loops is present, especially in the caudal abdomen. They contain a mixture of gas and fluid. The diameter of the entire descending colon and rectum is increased and both are filled with gas.

Neutered Male The sublumbar region appears physiological.

AGE Organomegaly of parenchymal organs does not appear to be present.

15 Years **RADIOGRAPHIC DIAGNOSIS**

- INTERPRETED BY**
- Emaciation
 - Localized ileus
 - Megacolon

Heike Rudolf, DVM,
 Dr. med. Vet.,
 DipECVDI DVR

INTERPRETATION OF THE FINDINGS & FURTHER RECOMMENDATIONS

HOSPITAL NAME The lack of intraabdominal fat makes organ assessment difficult but the negative contrast in the intestinal tract suggests an ileus. The cause may be obstructive (e.g. lymphoma) or related to hypoperistalsis as occurs in feline dysautonomia. The latter, however, is usually observed in animals younger than 3 years. Abdominal ultrasound is recommended to assess gastro-intestinal wall thickness and layering. Chronic renal disease should be ruled out. Exocrine pancreatic should be considered in animals with voluminous stools and serum feline trypsin-like immunoreactivity concentration is the diagnostic test of choice.

Harmony AH

REFERRING VET

Dr. Alexandra Peters

INVOICE

15764

DATE

5/27/22



PATIENT

Friday Pickell

SPECIES

Feline

BREED

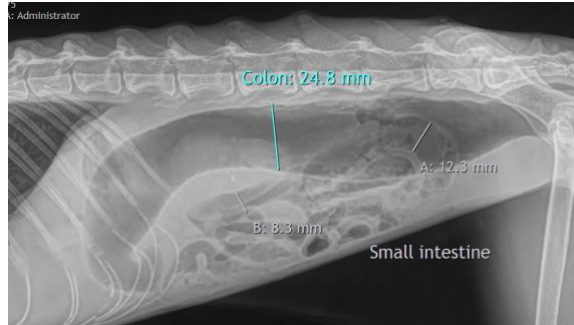
DSH

SEX

Neutered Male

AGE

15 Years



The information and recommendations provided are based on the images presented by the referring veterinarian/sonographer. No evaluation can be communicated regarding pathology that was not visible in the image/video clips provided.

Thank you for this referral. If the clinical or image interpretation does not parallel your findings or if I can be of any further assistance please contact me.

Heike Rudorf, DVM, Dr. med. vet., DipECVDI, DVR
dr.h.rudorf@gmail.com

INTERPRETED BY

Heike Rudorf, DVM,
Dr. med. Vet.,
DipECVDI DVR

HOSPITAL NAME

Harmony AH

REFERRING VET

Dr. Alexandra Peters

INVOICE

15764

DATE

5/27/22