



PATIENT

Nova Krause

SPECIES

Canine

BREED

Golden Retriever Mix

SEX

Female

AGE

4 Years 4 Months

WEIGHT

46.8 Pounds

INTERPRETED BY

Heike Rudorf, DVM, Dr.
med. Vet., DipECVDI
DVR

IMAGING PERFORMED BY

Kevin McClung

HOSPITAL NAME

Elizabeth AH

REFERRING VET

Kim Allyn, DVM

INVOICE

37169

DATE

5/22/26

PRESENTING CLINICAL SIGNS

History: Vomited a toddler's sock 3-4 days ago, has been vomiting and not eating for 3-4 days and acting lethargic.

Abnormal PE/Chem/CBC/UA Results: PE: Hydration: Dehydrated (5-10%) Abdomen: Full cranially, mild discomfort cranially, firm fecal balls in colon Gastrointestinal System: Uncomfortable to palpation of cranial abdomen, fecal balls palpated in colon.

RADIOGRAPHIC STUDY OF THE ABDOMEN

The body condition score is 4/9 with smooth, with tucked in lateral walls.

The bony structures appear physiological.

The abdominal organs are surrounded by very little fat; diaphragm and abdominal wall are intact.

The spleen appears physiological.

The stomach contains a small amount of air. The small intestine is generally filled with gas and appears slightly tortuous with stacking in the right cranial abdomen. The luminal content is of soft tissue opacity with a network of thin, lucent lines just caudal to the asc. colon and to the right of L4. On the lateral view, localized regions of ileus are present and associated with the striated soft tissue opacity. The colon contains solid, formed feces.

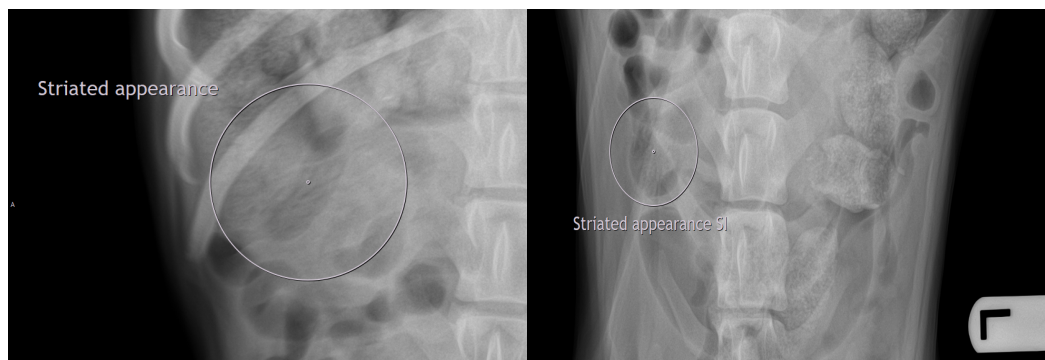
As far as visible, the other structures appear physiological.

RADIOGRAPHIC DIAGNOSIS

- Ileus
- Cloth foreign body/-ies
- Thin animal

INTERPRETATION OF THE FINDINGS & FURTHER RECOMMENDATIONS

The changes are highly suspicious for cloth foreign bodies in the mid, right small intestine which would fit the history. The owners should be advised to check for missing socks and other cloth material. Ultrasound can be performed to confirm the suspicion. However, the combination of history, length and persistence of clinical signs in combination with the radiographic findings will lead to surgery.





Teleradiology

Educational Teleconsultation Services™

PATIENT

Nova Krause

SPECIES

Canine

BREED

Golden Retriever Mix

SEX

Female

AGE

4 Years 4 Months

WEIGHT

46.8 Pounds

INTERPRETED BY

Heike Rudorf, DVM, Dr.
med. Vet., DipECVDI
DVR

IMAGING PERFORMED BY

Kevin McClung

HOSPITAL NAME

Elizabeth AH

REFERRING VET

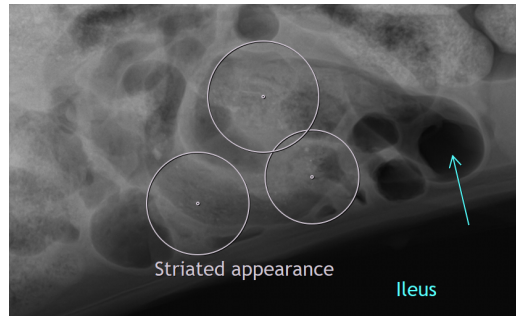
Kim Allyn, DVM

INVOICE

37169

DATE

5/22/26



The information and recommendations provided are based on the images presented by the referring veterinarian/sonographer. No evaluation can be communicated regarding pathology that was not visible in the image/video clips provided.

Thank you for this referral. If the clinical or image interpretation does not parallel your findings or if I can be of any further assistance, please contact me.

Heike Rudorf, DVM, Dr. med. vet., DipECVDI, DVR
info@sonopath.com