



PATIENT

Luno Arroyo

SPECIES

Canine

BREED

French Bulldog

SEX

Spayed Female

AGE

6 Years

WEIGHT

11 kg

INTERPRETED BY

Heike Rudolf, DVM, Dr.
med. Vet., DipECVDI
DVR

IMAGING PERFORMED BY

JS

HOSPITAL NAME

Green Dog Dental and
Wellness

REFERRING VET

Dr. Rally

INVOICE

16454

DATE

05/22/26

PRESENTING CLINICAL SIGNS

O reported intermittent L hindleg lameness, non-weight bearing.

RADIOGRAPHIC STUDY OF PELVIS AND STIFLES

R/L lateral and VD, totaling four radiographs provided for interpretation.

22.05.2026

RADIOGRAPHIC FINDINGS

Hind legs

The skin surfaces are smooth, and the muscles appear to be symmetrically developed.

The long bones are well mineralized, have a normal trabecular structure and smooth, continuous surfaces. Cortico-medullary development and differentiation of the long bones are physiological.

Pelvis: osseous and surrounding soft tissue structures of the pelvis are within normal limits. The center of both femoral heads is located medial to the respective dorsal acetabular edge. Both coxo-femoral joints present smooth osseous margins and congruent joint spaces.

Stifle L: the joint presents with smooth, subchondral bone surfaces and the center of the femoral condyles is in line with the intercondylar eminence of the tibia. A centrally located soft tissue opacity reduces the cranial fat pad. The caudal fascial plains are in a physiological position. A small amount of new bone (NB) formation is present on fabellae and patella.

Stifle R: Similar changes to the left are present.

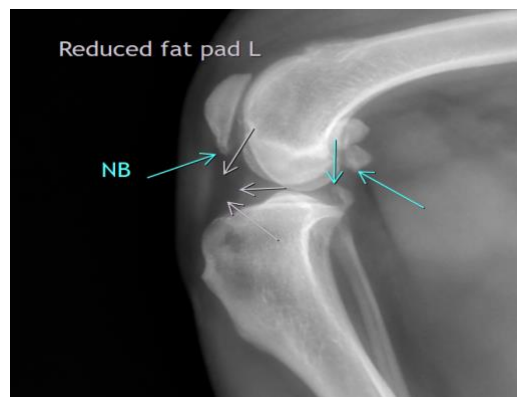
RADIOGRAPHIC DIAGNOSIS

Stifles

- Small effusion
- Arthrosis, mild

INTERPRETATION OF THE FINDINGS & FURTHER RECOMMENDATIONS

Changes are present in both stifle joints thus do not explain a unilateral lameness. Should clinical examination under sedation not show a drawer sign on the left, myositis of the popliteal or gastrocnemius muscles may be present. Pain associated with unilateral disc disease is a differential diagnosis. In those cases, cross sectional imaging is necessary for a diagnosis.





PATIENT

Luno Arroyo

SPECIES

Canine

BREED

French Bulldog

SEX

Spayed Female

AGE

6 Years

WEIGHT

11 kg

INTERPRETED BY

Heike Rudolf, DVM, Dr.
med. Vet., DipECVDI
DVR

IMAGING PERFORMED BY

JS

HOSPITAL NAME

Green Dog Dental and
Wellness

REFERRING VET

Dr. Rally

INVOICE

16454

DATE

05/22/26

The information and recommendations provided are based on the images presented by the referring veterinarian/sonographer. No evaluation can be communicated regarding pathology that was not visible in the image/video clips provided.

Thank you for this referral. If the clinical or image interpretation does not parallel your findings or if I can be of any further assistance, please contact me.

Heike Rudolf, DVM, Dr. med. vet., DipECVDI, DVR
info@sonopath.com