

**PATIENT**

Jakob Fenner

PRESENTING CLINICAL SIGNS

Gradual decrease in appetite and diarrhea over 2 days with urgency that progressed to severe hematochezia.

SPECIES

Canine

Abnormal PE/Chem/CBC/UA Results: PE: Unremarkable, just a bit more tired than usual.

RADIOGRAPH OF THE ABDOMEN

R and I lateral, 2x VD

BREED

Golden Retriever

RADIOGRAPHIC FINDINGS

The body condition score is 4-5/9 with smooth alternating layers of fat and soft tissue opacity.

The bony structures appear physiological.

SEX

Male

The stomach is empty; stacking of air-filled small intestinal loops in the caudal abdomen is present on both VD views, gas distension of one small intestinal loop in the left hemiabdomen is only evident on one VD view. On the lateral views the caudo-ventral small intestine presents as looped structures and in right lateral recumbency fecal matter presents itself in a stacked line. Colon and rectum are virtually empty.

AGE

5 Years, 9 Months

The other visible abdominal organs appear physiological.

RADIOGRAPHIC DIAGNOSIS

- Localized ileus
- Stacking of small intestinal loops

INTERPRETED BY

Heike Rudorf, DVM,
Dr. med. Vet.,
DipECVDDI DVR

INTERPRETATION OF THE FINDINGS & FURTHER RECOMMENDATIONS

The changes are suggestive of a partial intestinal obstruction and abdominal ultrasound is recommended to rule out (linear) foreign body and intestinal tumor. Alternatively, a barium follow through is possible but will take a long time and the Barium passage may be hampered by decreased intestinal motility.

HOSPITAL NAME

Elizabeth Animal
Hospital

REFERRING VET

Leon Anderson, DVM

INVOICE

52130

DATE

5-12-22



PATIENT

Jakob Fenner

SPECIES

Canine

BREED

Golden Retriever

SEX

Male

AGE

5 Years, 9 Months

INTERPRETED BY

Heike Rudorf, DVM,
Dr. med. Vet.,
DipECVDI DVR

HOSPITAL NAME

Elizabeth Animal
Hospital

REFERRING VET

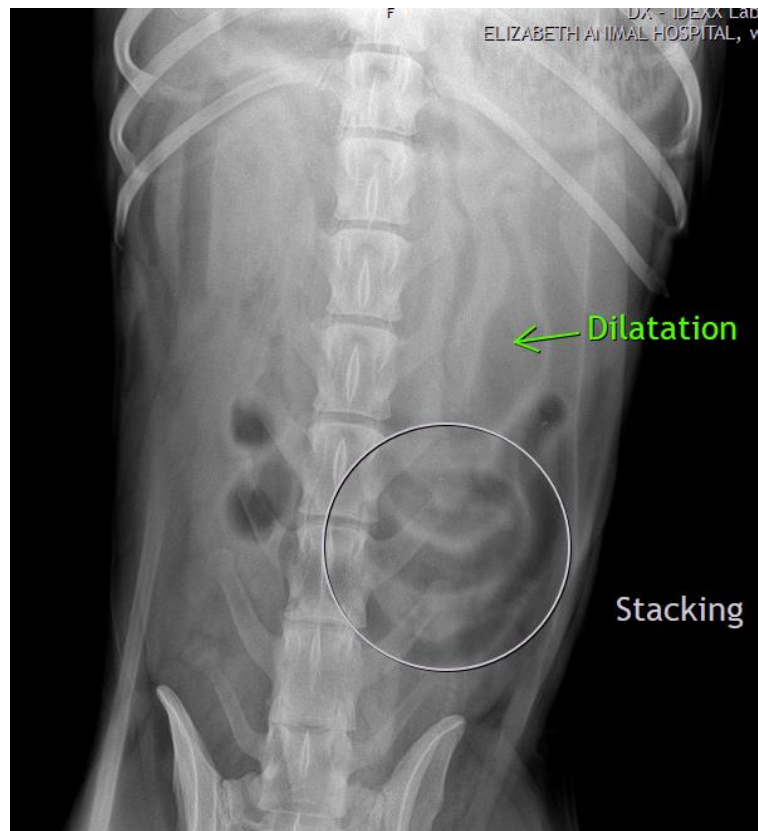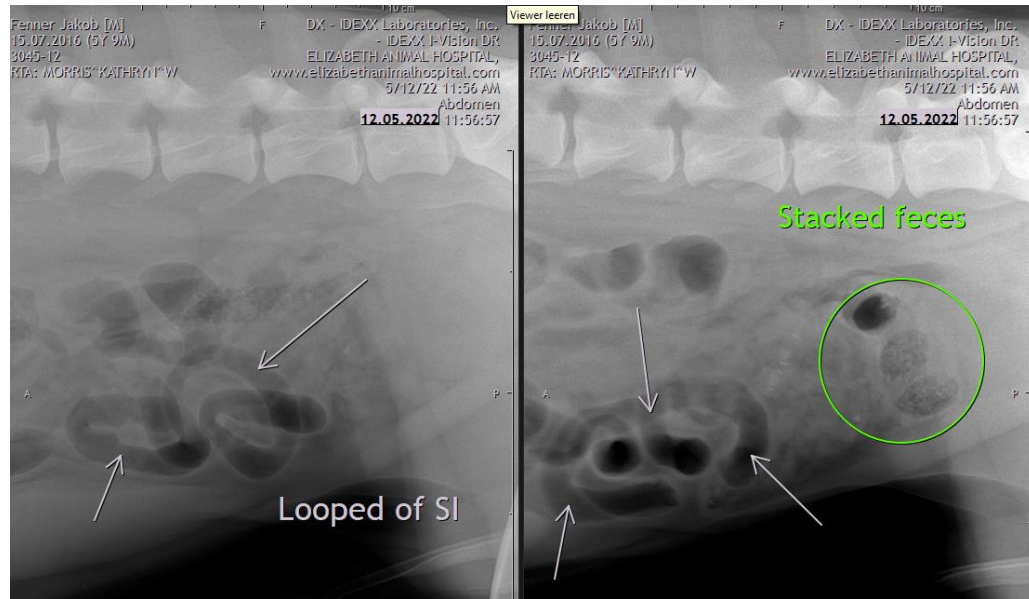
Leon Anderson, DVM

INVOICE

52130

DATE

5-12-22





PATIENT

Jakob Fenner

The information and recommendations provided are based on the images presented by the referring veterinarian/sonographer. No evaluation can be communicated regarding pathology that was not visible in the image/video clips provided.

SPECIES

Canine

Thank you for this referral. If the clinical or image interpretation does not parallel your findings or if I can be of any further assistance please contact me.

BREED

Golden Retriever

Heike Rudolf, DVM, Dr. med. vet., DipECVDI, DVR
Dr.H.Rudorf@gmail.com

SEX

Male

AGE

5 Years, 9 Months

INTERPRETED BY

Heike Rudolf, DVM,
Dr. med. Vet.,
DipECVDI DVR

HOSPITAL NAME

Elizabeth Animal
Hospital

REFERRING VET

Leon Anderson, DVM

INVOICE

52130

DATE

5-12-22