



PATIENT

Caspian Tsemblerlis

SPECIES

Canine

BREED

Coonhound Mix

SEX

Neutered Male

AGE

12 Years

WEIGHT

72

INTERPRETED BY

Heike Rudolf, DVM, Dr.
med. Vet., DipECVDDI
DVR

IMAGING PERFORMED BY

CHP

HOSPITAL NAME

Hamburg Veterinary
Clinic

REFERRING VET

Dr. DenHever

INVOICE

15715

DATE

05/01/26

PRESENTING CLINICAL SIGNS

Stumbles, loses balance

RADIOGRAPHIC STUDY OF THE PELVIS

L lateral and VD, totaling 2 radiographs provided for interpretation.

01.05.2026

RADIOGRAPHIC FINDINGS

Hind legs: The skin surfaces are smooth, and the muscles appear to be symmetrically developed.

All bones are well mineralized, have a normal trabecular structure and smooth, continuous surfaces. Cortico-medullary development and differentiation of the long bones are physiological.

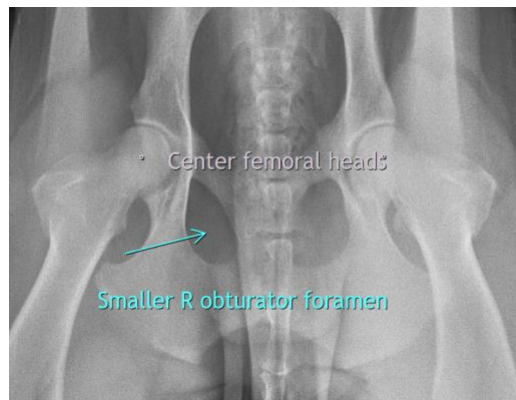
Pelvis: taking into account the mild tilting to the right, the center of both femoral heads is superimposed onto the respective dorsal acetabular edge. Both coxo-femoral joints present smooth osseous margins and congruent joint spaces.

RADIOGRAPHIC DIAGNOSIS

- Physiological study

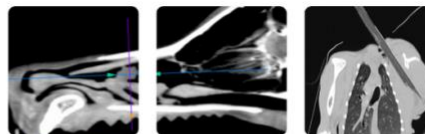
INTERPRETATION OF THE FINDINGS & FURTHER RECOMMENDATIONS

Reluctance to fully extend the legs, even under sedation, can be due to pain or bone disease. However, I can see no bony changes that would explain the clinical signs. Soft tissue injuries have to be considered, and cross-sectional imaging may be helpful, especially to rule out myositis of the origin of the gastrocnemius muscles. Disc disease may be present, but cord compression can only be identified with myelography or in cross-sectional imaging. In case neurological deficits and/or spinal pain unresponsive to medical management, are present, CT or MRI is recommended. Prior to this, cruciate disease should be ruled out if it has not already been done.



The information and recommendations provided are based on the images presented by the referring veterinarian/sonographer. No evaluation can be communicated regarding pathology that was not visible in the image/video clips provided.

Thank you for this referral. If the clinical or image interpretation does not parallel your findings or if I can be of any further assistance, please contact me.



PATIENT

Caspian Tsemberlis

Heike Rudolf, DVM, Dr. med. vet., DipECVDI, DVR
info@sonopath.com

SPECIES

Canine

BREED

Coonhound Mix

SEX

Neutered Male

AGE

12 Years

WEIGHT

72

INTERPRETED BY

Heike Rudolf, DVM, Dr.
med. Vet., DipECVDI
DVR

IMAGING PERFORMED BY

CHP

HOSPITAL NAME

Hamburg Veterinary
Clinic

REFERRING VET

Dr. DenHever

INVOICE

15715

DATE

05/01/26