



PATIENT PRESENTING CLINICAL SIGNS

Leeloo Rivera History: Limping on R front leg for the past 48 hours after running around.
Abnormal PE/Chem/CBC/UA Results: Severe swelling of the 4th digit of the R front paw.

SPECIES RADIOGRAPHIC STUDY OF THE RIGHT FORE PAW

Canine Marked soft tissue swelling surrounds digit 4. On the DP view angulation of P3 in relation to P2 is altered compared to the other digits and P3 is partially superimposed onto P2 on the medial aspect. On the lateral and lateral oblique views the joint appears physiological.

BREED Mild soft tissue swelling surrounds a round bone opacity medial to the distal cortex of metacarpus 2. The cortex at this level partially surrounds the bony structure.

Labrador Mix The radius shows cranial bowing and lateral deviation of the paw is present. Small osteophytes are present on distal radius, carpal bones and one metacarpus.

SEX RADIOGRAPHIC DIAGNOSIS

Spayed Female Digit 4

- Soft tissue swelling
- Altered joint surface P2/3

AGE 6 Years 2 Months Incidental finding

- Angular limb deformity

INTERPRETED BY Arthrosis

Heike Rudolf, DVM, Dr. med. Vet., DipECVDI DVR

- metacarpo-phalangeal joint digit 2
- radiocarpal joint

INTERPRETATION OF THE FINDINGS & FURTHER RECOMMENDATIONS

HOSPITAL NAME Northvale VC Looking at history and radiographic evidence a soft tissue trauma is the most likely reason for the swelling. Ligament and joint capsule may be involved and a subluxation may be present, thus manual examination is necessary once the swelling has subsided. I can see no fracture line but a hairline fissure would not be immediately evident. It takes up to 12 days before the osteoclastic activity has resulted in widening that can be appreciated radiographically. Should the angular limb deformity only be present on the right, this may predispose the dog to traumatic injuries. I suggest conservative treatment and re-examination in 2-3 weeks.

REFERRING VET Dr. Stefanie Simon

INVOICE

21926

DATE

4/7/23



PATIENT

Leeloo Rivera

SPECIES

Canine

BREED

Labrador Mix

SEX

Spayed Female

AGE

6 Years 2 Months

INTERPRETED BY

Heike Rudolf, DVM,
Dr. med. Vet.,
DipECVDI DVR

HOSPITAL NAME

Northvale VC

REFERRING VET

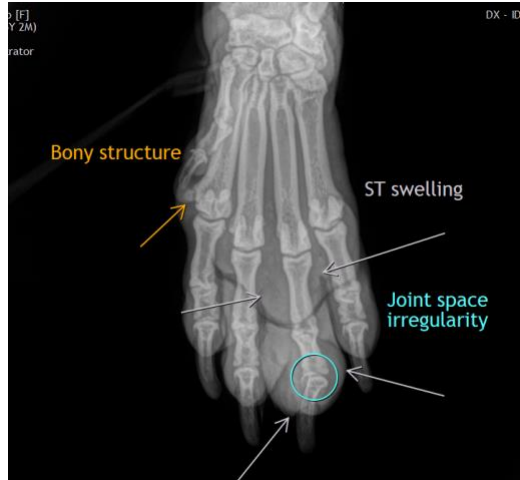
Dr. Stefanie Simon

INVOICE

21926

DATE

4/7/23



The information and recommendations provided are based on the images presented by the referring veterinarian/sonographer. No evaluation can be communicated regarding pathology that was not visible in the image/video clips provided.

Thank you for this referral. If the clinical or image interpretation does not parallel your findings or if I can be of any further assistance please contact me.

Heike Rudolf, DVM, Dr. med. vet., DipECVDI, DVR
dr.h.rudorf@gmail.com