



PATIENT PRESENTING CLINICAL SIGNS

Dakota Panich History of mast cell tumor on anus and leg and oral melanoma. Dog is urinating and defecating everywhere with diarrhea. PU/PP/PD (currently on steroids). Dog snores when sleeping and pants when awake but no coughing.

SPECIES Abnormal PE/Chem/CBC/UA Results: Lungs auscultate harsh. Dermal masses all over body, limbs, head and anus.
Canine

RADIOGRAPHIC STUDY OF THE ABDOMEN

BREED Multiple, confluent, nodular mass lesions are present throughout the included lung fields. Hardly any aerated lung tissue is present.
Cockapoo

Multiple soft tissue masses protrude beyond the skin surfaces.

SEX T13- L3 show ventral spondylosis; disc space width appears reduced, especially at T13/L1. The abdominal detail is reasonable; diaphragm and abdominal wall are intact.
Neutered Male

The liver is located within the costal arch and the caudo-ventral lobe is pointed.

AGE The head of the spleen appears physiological.
12 Years 2 Months

The stomach is moderately distended with air and food; distribution of the small intestinal loops appears physiological; their size and contents vary. The colon is ventrally displaced and contains a small amount of gas. The rectum is likely also ventrally displaced by a large amount of soft tissue ventral to the tail.

INTERPRETED BY

Heike Rudolf, DVM, Dr. med. Vet., DipECVDI DVR The urinary tract appears physiological.

The sublumbar region shows multiple round and oval shaped soft tissue masses.

HOSPITAL NAME RADIOGRAPHIC DIAGNOSIS

- Northvale VC**
- Lung metastases, multiple and severe
 - Sublumbar masses
 - Subcutaneous masses

REFERRING VET

Dr. Stefanie Simon Incidental findings

- Spondylosis
- Possible disc disease

INVOICE

21925

INTERPRETATION OF THE FINDINGS & FURTHER RECOMMENDATIONS

The changes are compatible with metastatic tumor spread. This may be the result of one of the previously detected tumors or a third tumor elsewhere; differentiation is academic and the prognosis is in poor. Involvement of the intestinal tract can best be seen ultrasonographically.

DATE

4/7/23



PATIENT

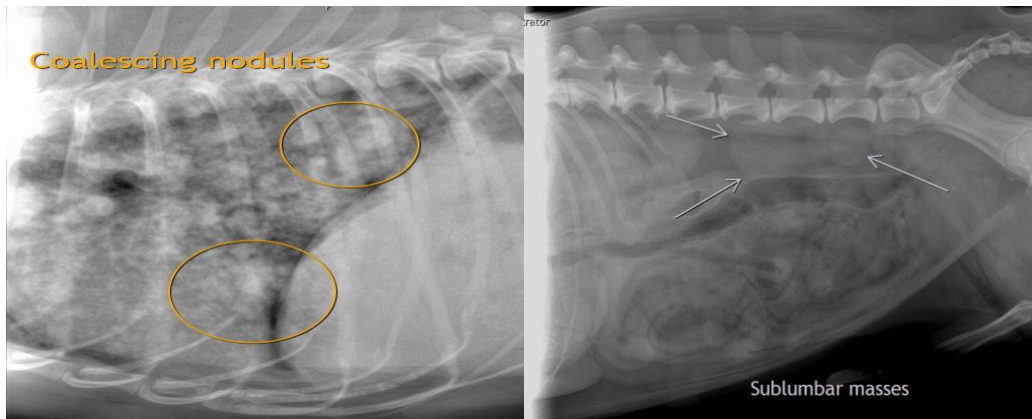
Dakota Panich

SPECIES

Canine

BREED

Cockapoo



SEX

Neutered Male

The information and recommendations provided are based on the images presented by the referring veterinarian/sonographer. No evaluation can be communicated regarding pathology that was not visible in the image/video clips provided.

AGE

12 Years 2 Months

Thank you for this referral. If the clinical or image interpretation does not parallel your findings or if I can be of any further assistance please contact me.

Heike Rudorf, DVM, Dr. med. vet., DipECVDI, DVR
dr.h.rudorf@gmail.com

INTERPRETED BY

Heike Rudorf, DVM,
Dr. med. Vet.,
DipECVDI DVR

HOSPITAL NAME

Northvale VC

REFERRING VET

Dr. Stefanie Simon

INVOICE

21925

DATE

4/7/23