



PATIENT PRESENTING CLINICAL SIGNS

Brynlee Fitzsimmons History: P limping on one of hind legs ~ 1mo. O unsure of which one. Has not improved with gabapentin.

SPECIES Abnormal PE/Chem/CBC/UA Results: Unable to examine p without sedation. Limping right hind. Little movement on either stifle

Canine RADIOGRAPHIC STUDY OF THE PELVIS AND STIFLES

BREED The skin surfaces are smooth, and the muscles appear to be symmetrically developed. All bones are well mineralized, have a normal trabecular structure and a smooth surface. Cortical-medullary development and differentiation of the long bones are physiological.

Lab

Pelvis

SEX The centre of both femoral heads is superimposed onto the respective dorsal acetabular edge. Both hip joints appear congruent with even subchondral bone surfaces. No new bone formation is evident. Spayed Female A small, crescent shaped bone opacity is located at the proximal aspect of the lesser tubercle on the right.

AGE Stifles

7 Years

Both stifle joints have smooth subchondral bone surfaces and the centre of the femoral condyles is in line with the intercondylar eminence. The cranial fat pad has a physiological size and the caudal fascial plains are in a physiological position. New bone formation is not evident and the patellae are located in their respective groove.

INTERPRETED BY

Heike Rudolf, DVM,
Dr. med. Vet.,
DipECVDI DVR

Tarsi

The central portion of both tibio-tarsal joints shows an increased width. A small fragment is located dorsal to the right trochlea.

HOSPITAL NAME

The Pet Hospital of
Stratford

RADIOGRAPHIC DIAGNOSIS

- Mineral deposit tendon of M. isliopsoas R
- Possible bilateral hock OCD
 - Joint mouse R tibio-tarsal joint
- Mild HD, bilateral

REFERRING VET

Dr. Claudia Giuliani,
DVM

INTERPRETATION OF THE FINDINGS & FURTHER RECOMMENDATIONS

Considering the age and the smooth surfaces of the hock joints, it is unlikely that tarsal OCD is the reason for the lameness. However, dislodgement of a joint mouse may have only just occurred and thus clinical examination may have to be followed by DP views of both tarsi. In agile dogs soft tissue changes such as gastrocnemius myositis, disc protrusion and neuropathies of the lumbar plexus have to be considered. Cross sectional imaging will help rule out these diseases and allow assessment of the iliopsoas muscles. Sedation may be necessary for a meaningful clinical examination.

INVOICE

21923

DATE

4/7/23



PATIENT

Brynlee Fitzsimmons

SPECIES

Canine

BREED

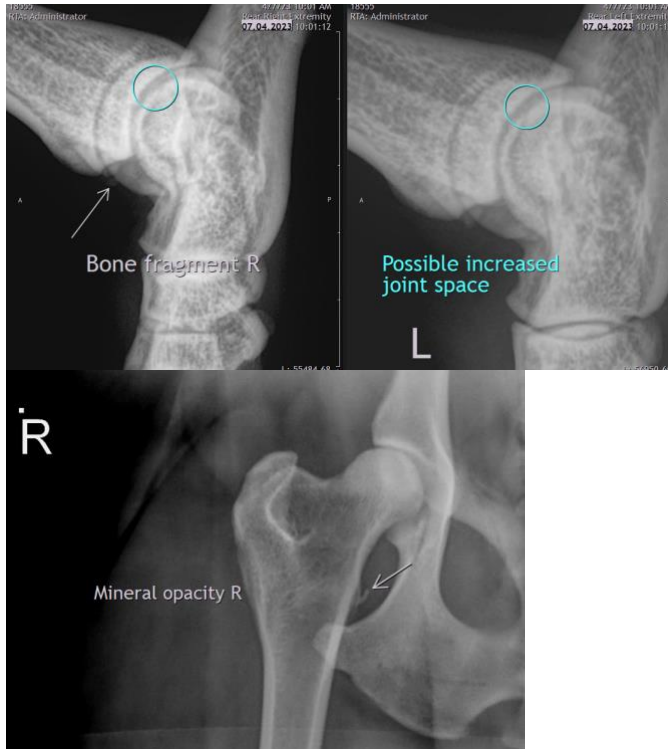
Lab

SEX

Spayed Female

AGE

7 Years



INTERPRETED BY

Heike Rudolf, DVM,
Dr. med. Vet.,
DipECVDI DVR

The information and recommendations provided are based on the images presented by the referring veterinarian/sonographer. No evaluation can be communicated regarding pathology that was not visible in the image/video clips provided.

Thank you for this referral. If the clinical or image interpretation does not parallel your findings or if I can be of any further assistance please contact me.

HOSPITAL NAME

The Pet Hospital of
Stratford

Heike Rudolf, DVM, Dr. med. vet., DipECVDI, DVR
dr.h.rudorf@gmail.com

REFERRING VET

Dr. Claudia Giuliani,
DVM

INVOICE

21923

DATE

4/7/23