



PATIENT

Compadre Sergio

SPECIES

Canine

BREED

Shepherd Mix

SEX

Male Neutered

AGE

12Y

WEIGHT

58lbs

INTERPRETED BY

Heike Rudolf, DVM, Dr.
med. Vet., DipECVDI
DVR

IMAGING PERFORMED BY

Dr. Anderson

HOSPITAL NAME

Animal Clinic of
Queens

REFERRING VET

Dr. Anderson

INVOICE

74459

DATE

4-6-26

PRESENTING CLINICAL SIGNS

Pt rescued from Mexico, RH limb amputee.

HM 2/6

Moderate dental dz. Full workup before dental procedure.

RADIOGRAPHS OF THORAX AND ABDOMEN

R/L lateral and VD, totaling 7 radiographs provided for interpretation.

RADIOGRAPHIC FINDINGS

The body condition score is 6/9 with smooth, alternating layers of fat and soft tissue opacity.

The bony structures are within normal limits.

Thorax

The cranial mediastinum is of physiological size and opacity. The trachea runs parallel to the thoracic vertebrae and dips at the carina.

The left lung lobes are slightly retracted from the rib cage and a pleural fissure line is present. All lobes on the left show a decreased lucency due to the overlying pleural fluid.

The cardiac silhouette occupies 75% of the chest height and 2.5 intercostal spaces. Chamber or outflow tract enlargement is not obvious.

Abdomen

The abdominal organs are surrounded by fat; diaphragm and abdominal wall are intact.

The liver is located just within the costal arch, and the caudo-ventral lobe is pointed.

The spleen appears physiological and is in contact with the ventral liver lobe.

The stomach is moderately distended with food. Distribution and size of the intestinal loops appear physiological.

Only the right renal shadow is visible on the VD view and has a physiological size, shape and opacity. The left is obscured by intestinal content. The bladder is empty and the neck located in the pelvic canal.

The sublumbar region appears physiological.

RADIOGRAPHIC DIAGNOSIS

- Pleural fluid, left

INTERPRETATION OF THE FINDINGS & FURTHER RECOMMENDATIONS

Unilateral pleural fluid is usually due to chyle or an exudate. Ultrasound guided tapping is recommended. Cytology and bacteriology are recommended in case a mesothelioma is present. Cardiac ultrasound should be performed if a transudate is present.



PATIENT

Compadre Sergio

SPECIES

Canine

BREED

Shepherd Mix

SEX

Male Neutered

AGE

12Y

WEIGHT

58lbs

INTERPRETED BY

Heike Rudolf, DVM, Dr.
med. Vet., DipECVDI
DVR

IMAGING PERFORMED BY

Dr. Anderson

HOSPITAL NAME

Animal Clinic of
Queens

REFERRING VET

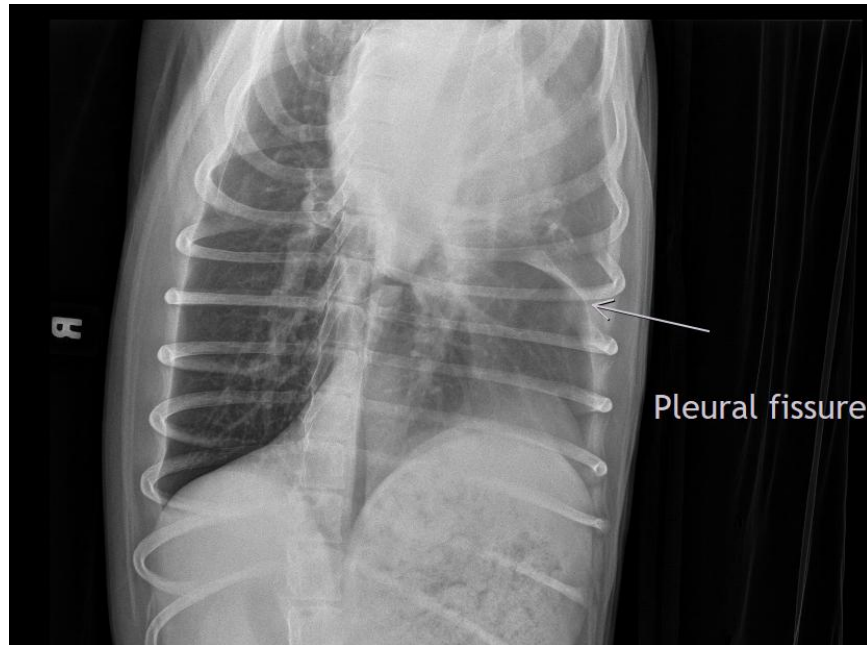
Dr. Anderson

INVOICE

74459

DATE

4-6-26



The information and recommendations provided are based on the images presented by the referring veterinarian/sonographer. No evaluation can be communicated regarding pathology that was not visible in the image/video clips provided.

Thank you for this referral. If the clinical or image interpretation does not parallel your findings or if I can be of any further assistance, please contact me.

Heike Rudolf, DVM, Dr. med. vet., DipECVDI, DVR
info@sonopath.com