



PATIENT

Theodore Dawson

SPECIES

Feline

BREED

DSH

SEX

Neutered Male

AGE

9 Years 9 Months

WEIGHT

11.7 pounds

INTERPRETED BY

Heike Rudolf, DVM, Dr.
med. Vet., DipECVDDI
DVR

IMAGING PERFORMED BY

Mary Krueger LVT

HOSPITAL NAME

Gentle Doctor Animal
Hospital

REFERRING VET

Dr. Sergio Valadez

INVOICE

14872

DATE

04/04/26

PRESENTING CLINICAL SIGNS

Acute presentation of ataxia and proprioceptive deficits bilaterally in the hind legs. Firm palpable stool noted in the colon, concern for constipation.

Abnormal PE/Chem/CBC/UA Results: Ataxia and proprioceptive deficits bilaterally in the hind legs. Mild discomfort palpable in lumbosacral region. Deep pain present but falling over when standing. Bladder is distended. Blood glucose: 267, history of stress hyperglycemia, recent Fructosamine was within normal limits.

RADIOGRAPHIC STUDY OF THE L-SPINE

R/L lateral and VD, totaling 3 radiographs provided for interpretation.

04.04.2026

RADIOGRAPHIC FINDINGS

The surrounding soft tissue structures appear physiological.

Number and shape of the vertebrae are physiological; their surfaces are smooth. No evidence of osseous destruction or lysis is present along the spine.

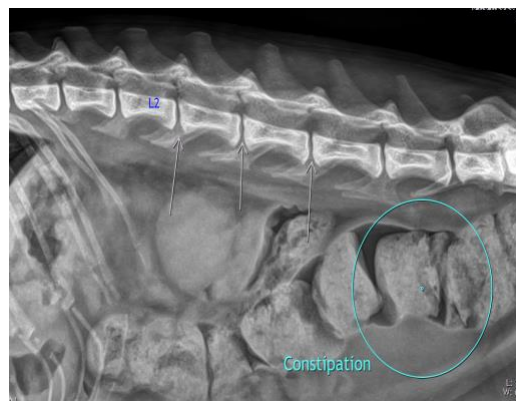
The disc spaces between L2 and L5 are slightly reduced on the lateral views; on the VD they are spaced evenly.

RADIOGRAPHIC DIAGNOSIS

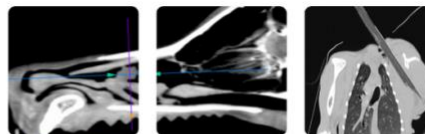
- Constipation
- L2-5: mildly reduced disc spaces

INTERPRETATION OF THE FINDINGS & FURTHER RECOMMENDATIONS

Accurate positioning of the spine is difficult, even under G.A., and cord compression can only be identified with myelography or in cross-sectional imaging. Because of the described neurological signs CT or MRI of the entire spine is recommended. CSF analysis may be necessary to rule out lymphoma. Manual evacuation of the large intestine is recommended.



The information and recommendations provided are based on the images presented by the referring veterinarian/sonographer. No evaluation can be communicated regarding pathology that was not visible in the image/video clips provided.



PATIENT

Theodore Dawson

SPECIES

Feline

BREED

DSH

SEX

Neutered Male

AGE

9 Years 9 Months

WEIGHT

11.7 pounds

INTERPRETED BY

Heike Rudolf, DVM, Dr.
med. Vet., DipECVDI
DVR

IMAGING PERFORMED BY

Mary Krueger LVT

HOSPITAL NAME

Gentle Doctor Animal
Hospital

REFERRING VET

Dr. Sergio Valadez

INVOICE

14872

DATE

04/04/26

Thank you for this referral. If the clinical or image interpretation does not parallel your findings or if I can be of any further assistance, please contact me.

Heike Rudolf, DVM, Dr. med. vet., DipECVDI, DVR
info@sonopath.com