



PATIENT

Teddy Cunningham

SPECIES

Canine

BREED

Yorkie

SEX

Neutered Male

AGE

11 Years

WEIGHT

3.7 kg

INTERPRETED BY

Heike Rudolf, DVM, Dr.
med. Vet., DipECVDD
DVR

IMAGING PERFORMED BY

RVT

HOSPITAL NAME

Windermere
Veterinary Hospital

REFERRING VET

Dr. Dani Wood

INVOICE

14871

DATE

04/04/26

PRESENTING CLINICAL SIGNS

Sudden onset dry hacking cough,

Abnormal PE/Chem/CBC/UA Results: Coughing with tracheal palpation. No bloodwork or urine done.

RADIOGRAPHIC STUDY OF THE THORAX

R/L lateral and VD are provided, totaling 4 radiographs for interpretation.

04.04.2026

RADIOGRAPHIC FINDINGS

The body condition score is 7-8/9 with smooth, alternating layers of fat and soft tissue opacity.

The manubrium sterni is short.

The cranial mediastinum is of physiologic size and opacity. The trachea runs parallel to the thoracic vertebrae and is in line with the carina. Tracheal height is increased in the thoracic inlet. A soft tissue opacity first reduces and the completely obscures the air shadow in the tracheal lumen between C3 and T3.

The degree of pulmonary expansion is fair, the dome of the diaphragm is superimposed onto the caudal heart border. The lung lobes are slightly displaced from the thoracic boundaries by fat. The tertiary vascular branches in the caudal lobes are blurred on the VD view. The bronchial tree is thin walled and tapers towards the periphery.

The cardiac silhouette occupies 90% of the chest height and 3.5 intercostal spaces (VHS=11). The caudal heart border is straight and tenting of the left atrium is present.

RADIOGRAPHIC DIAGNOSIS

- Tracheal collapse, severe
- Left sided cardiomegaly
- Interstitial pattern

Incidental finding

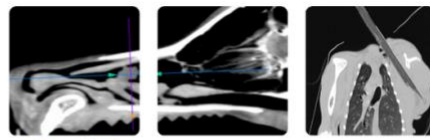
- Short manubrium sterni

INTERPRETATION OF THE FINDINGS & FURTHER RECOMMENDATIONS

Tracheal collapse is present. Tracheal collapse alone can be due to a weakened dorsal tracheal ligament. Tracheal in combination with bronchial collapse is usually due to an altered cartilage development which may go unnoticed until physical circumstances (such as stress, running, excitement) or disease (e.g., L cardiac enlargement, pneumonia, bronchitis) reduces the ease of airflow. The gold standard for imaging both pathologies is tracheo-bronchoscopy. A sample should be obtained for cytology and bacteriology if echocardiography reveals a normal anatomy and cardiogenic edema can thus be ruled out. Should an underlying disease be present treatment may improve the clinical signs.

An interstitial lung pattern is a non-specific finding and accentuated by the only fair expansion of the lung field and obesity. Possible differential diagnoses for a true infiltrate include:

- Edema
- Infection (bacterial, fungal e.g., candida, viral, Rickettsia, Spirochetes, parasitic e.g., angiostrongylus)



PATIENT

Teddy Cunningham

SPECIES

Canine

BREED

Yorkie

SEX

Neutered Male

AGE

11 Years

WEIGHT

3.7 kg

INTERPRETED BY

Heike Rudolf, DVM, Dr.
med. Vet., DipECVDI
DVR

IMAGING PERFORMED BY

RVT

HOSPITAL NAME

Windermere
Veterinary Hospital

REFERRING VET

Dr. Dani Wood

INVOICE

14871

DATE

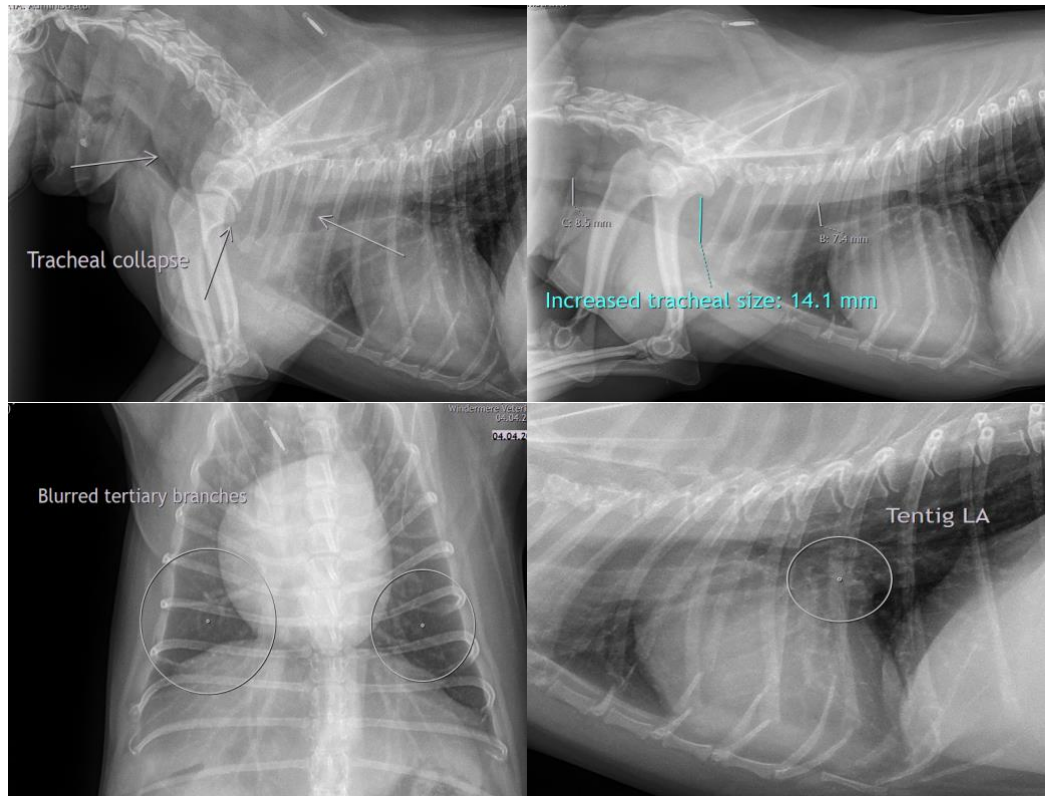
04/04/26

- Inflammation (allergic pneumonitis, eosinophilic bronchopneumopathy, smoke inhalation)

Less likely

- Diffuse hemorrhage
- Early idiopathic fibrosis
- Tumor (e.g., lymphoma)

Fecal samples can be obtained to rule out parasites.



The information and recommendations provided are based on the images presented by the referring veterinarian/sonographer. No evaluation can be communicated regarding pathology that was not visible in the image/video clips provided.

Thank you for this referral. If the clinical or image interpretation does not parallel your findings or if I can be of any further assistance, please contact me.

Heike Rudolf, DVM, Dr. med. vet., DipECVDI, DVR
info@sonopath.com