



## PATIENT

Kebbler Mitchell

## SPECIES

Feline

## BREED

DSH

## SEX

MN

## AGE

7Y, 8M

## WEIGHT

13.8

## INTERPRETED BY

Heike Rudolf, DVM, Dr.  
med. Vet., DipECVDI  
DVR

## IMAGING PERFORMED BY

Cathy Bond

## HOSPITAL NAME

Pocono Peak  
Veterinary Center

## REFERRING VET

Dr. Christine Coyle

## INVOICE

74829

## DATE

4-30-26

## PRESENTING CLINICAL SIGNS

Lameness shortly after visit in december 20525. O hearing clicking in FL leg. palpated normal in office on both visits

Abnormal PE/Chem/CBC/UA Results: Normal

## RADIOGRAPHS OF LEFT FORELEG AND THORAX

L lateral foreleg and R lateral thorax including both elbow joints, totaling 2 radiographs provided for interpretation.

## RADIOGRAPHIC FINDINGS

A large amount of intra-abdominal fat is present. The cranial heart border is ill defined.

The bones are well mineralized, have a normal trabecular structure and smooth, continuous surfaces. A bone spur is present on the cranio-dorsal edge of sternebra 2. Cortico-medullary development and differentiation of the long bones are physiological.

Shoulder R: the joint appears congruent with even subchondral bone surfaces.

Shoulder L: a small amount of new bone (NB) appears to arise from the caudal scapula. A small ossicle is located just caudal to the humeral head.

Elbow joints: the joints appear congruent with even surfaces. The periosteal surfaces are smooth.

Carpus L: all joints appear to be congruent.

## RADIOGRAPHIC DIAGNOSIS

L shoulder:

- Mild arthrosis
- Possible joint mouse

## INTERPRETATION OF THE FINDINGS & FURTHER RECOMMENDATIONS

The changes are equivocal and have to be judged in light of the clinical shoulder examination. To identify the position of the ossicle, a caudo-cranial view of the shoulder is recommended. Should a lameness develop contrast CT can help identify myositis and tendinitis. In case respiratory signs are present the chest radiograph may have to be repeated including an orthogonal view.



## PATIENT

Kebbler Mitchell

## SPECIES

Feline

## BREED

DSH

## SEX

MN

## AGE

7Y, 8M

## WEIGHT

13.8

## INTERPRETED BY

Heike Rudolf, DVM, Dr.  
med. Vet., DipECVDI  
DVR

## IMAGING PERFORMED BY

Cathy Bond

## HOSPITAL NAME

Pocono Peak  
Veterinary Center

## REFERRING VET

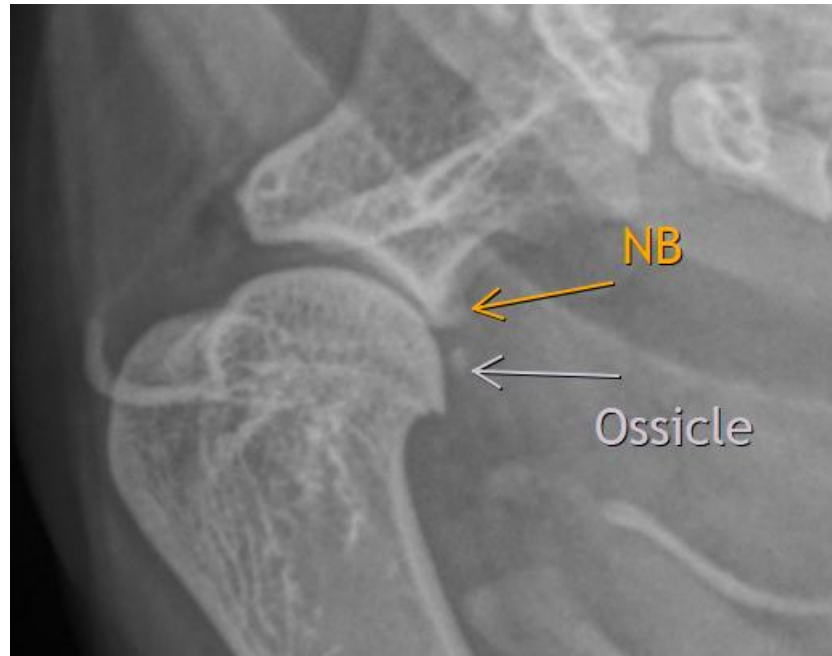
Dr. Christine Coyle

## INVOICE

74829

## DATE

4-30-26



The information and recommendations provided are based on the images presented by the referring veterinarian/sonographer. No evaluation can be communicated regarding pathology that was not visible in the image/video clips provided.

Thank you for this referral. If the clinical or image interpretation does not parallel your findings or if I can be of any further assistance, please contact me.

Heike Rudolf, DVM, Dr. med. vet., DipECVDI, DVR  
[info@sonopath.com](mailto:info@sonopath.com)