



## PATIENT

Luna Adams

## SPECIES

Canine

## BREED

Lab

## SEX

Spayed Female

## AGE

7 Years

## WEIGHT

53 Pounds

## INTERPRETED BY

Heike Rudorf, DVM, Dr.  
med. Vet., DipECVDI  
DVR

## IMAGING PERFORMED BY

Dr. Katie Maher

## HOSPITAL NAME

Maher AH

## REFERRING VET

Dr. Katie Maher

## INVOICE

36473

## DATE

4/3/26

## PRESENTING CLINICAL SIGNS

History: pain in left carpus noted weds. (2 days ago). Swelling of left carpus, on medial side. swelling feels hard, bony. Flexion of carpus elicits pain, as well as "hard palpation".

## RADIOGRAPHIC STUDY OF THE CARPI

The bones are well mineralized and have smooth, continuous surfaces. Cortico-medullary development and differentiation of the long bones are physiological.

Carpi/paws: a soft tissue swelling appears to be present on the medial and dorsal aspect of the carpus. A small amount of smooth new bone (NB) is located on the distal accessory carpal bone.

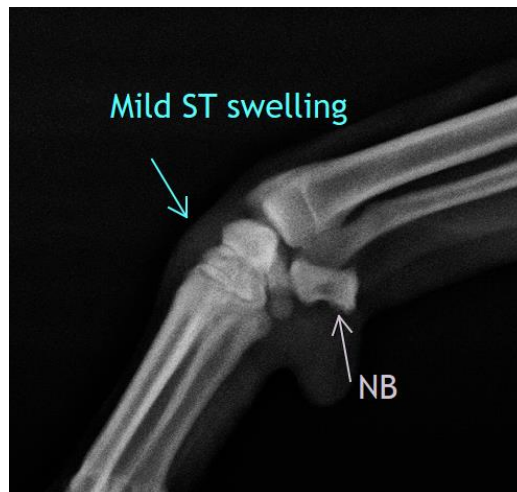
## RADIOGRAPHIC DIAGNOSIS

Left carpus

- Mild soft swelling
- Mild accessory carpal bone changes

## INTERPRETATION OF THE FINDINGS & FURTHER RECOMMENDATIONS

I can see no bony reason for the lameness. Ultrasounds of the visually identifiable mass is recommended, and a fine needle aspirate should be obtained for cytology, if possible,



**The information and recommendations provided are based on the images presented by the referring veterinarian/sonographer. No evaluation can be communicated regarding pathology that was not visible in the image/video clips provided.**

Thank you for this referral. If the clinical or image interpretation does not parallel your findings or if I can be of any further assistance, please contact me.

**Heike Rudorf**, DVM, Dr. med. vet., DipECVDI, DVR  
[info@sonopath.com](mailto:info@sonopath.com)