



PATIENT

Luca Mrsny

SPECIES

Canine

BREED

Golden Retriever

SEX

Neutered Male

AGE

11 Months

WEIGHT

56 Pounds

INTERPRETED BY

Heike Rudorf, DVM, Dr.
med. Vet., DipECVDI
DVR

IMAGING PERFORMED BY

Mary Krueger

HOSPITAL NAME

Gentle Doctor AH

REFERRING VET

Dr. Sydney Thorson

INVOICE

36474

DATE

4/3/26

PRESENTING CLINICAL SIGNS

History: Favoring left forelimb first noticed three months ago, improved temporarily but started to limp again 2 days ago. Will bear weight on the limb.

Abnormal PE/Chem/CBC/UA Results: Favors left forelimb when walking No pain with palpation

RADIOGRAPHIC STUDY OF SHOULDERS AND ELBOWS

The muscle mass is symmetrically developed and physiological.

The open growth plates are compatible with the given age.

The bones are well mineralized, have a normal trabecular structure and smooth, continuous surfaces. Cortico-medullary development and differentiation of the long bones are physiological.

Shoulders: the left humeral head appears slightly flatter than the right. Though both subchondral bone surfaces are smooth.

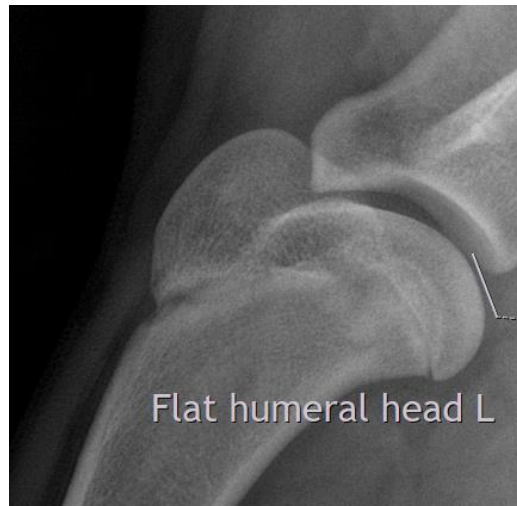Elbows: the joints appear congruent with even, subchondral and periosteal surfaces. Both medial coronoid processes appear physiologically smooth.

RADIOGRAPHIC DIAGNOSIS

- Mild flattening L humeral head

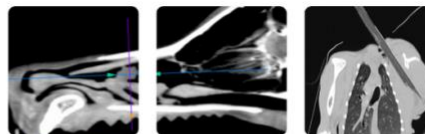
INTERPRETATION OF THE FINDINGS & FURTHER RECOMMENDATIONS

The described change is very subtle, and its significance is questionable. Soft tissue injury such as flexor myositis, digital flexor tendinitis and early panosteitis can only be ruled out in cross sectional imaging. Neuropathy (e.g., brachial plexus) in a dog this young is unlikely.



The information and recommendations provided are based on the images presented by the referring veterinarian/sonographer. No evaluation can be communicated regarding pathology that was not visible in the image/video clips provided.

Thank you for this referral. If the clinical or image interpretation does not parallel your findings or if I can be of any further assistance, please contact me.



PATIENT

Luca Mrsny

Heike Rudolf, DVM, Dr. med. vet., DipECVDI, DVR

info@sonopath.com

SPECIES

Canine

BREED

Golden Retriever

SEX

Neutered Male

AGE

11 Months

WEIGHT

56 Pounds

INTERPRETED BY

Heike Rudolf, DVM, Dr.
med. Vet., DipECVDI
DVR

**IMAGING
PERFORMED BY**

Mary Krueger

HOSPITAL NAME

Gentle Doctor AH

REFERRING VET

Dr. Sydney Thorson

INVOICE

36474

DATE

4/3/26