

PATIENT

Boots Diccico

SPECIES

Feline

BREED

DSH

SEX

Neutered Male

AGE

6 Years

WEIGHT

17.4 Pounds

INTERPRETED BY

Heike Rudorf, DVM, Dr.
med. Vet., DipECVDF
DVR

IMAGING PERFORMED BY

Mallory Frois

HOSPITAL NAME

The Pet Hospital of
Stratford

REFERRING VET

Dr. Claudia Giuliani

INVOICE

36472

DATE

4/3/26

PRESENTING CLINICAL SIGNS

O noted p licking hind end the past week

Diarrhea outside of box with blood this am

In and out of litter box several times and o noted small amount of urine

Vomited this am as well

Abnormal PE/Chem/CBC/UA Results: tpr - wnl abd - soft/non-painful on palpation unable to obtain urine sample and unable to palpate bladder obese

RADIOGRAPHIC STUDY OF THE ABDOMEN

The body condition score is 8/9 with smooth, alternating layers of fat and soft tissue opacity.

The bony structures are within normal limits.

The abdominal organs are surrounded by a large amount of fat; diaphragm and abdominal wall are intact.

The liver is located within the costal arch, and the caudo-ventral lobe is pointed.

The splenic shadow is not clearly outlined.

The stomach is moderately distended with air. The small intestinal loops vary in content and distribution as well as marginally in size. In the right cranio-ventral abdomen their gas content is more pronounced, and a circular loop is evident in both lateral recumbencies. Colon and rectum are thin and of soft tissue opacity.

Both renal shadows have a physiological size, shape and opacity. The bladder is moderately full and the bladder neck is located cranial to the pubic brim.

The sublumbar region appears physiological.

RADIOGRAPHIC DIAGNOSIS

- Obesity
- Small intestinal gas

INTERPRETATION OF THE FINDINGS & FURTHER RECOMMENDATIONS

I can see no radiopaque foreign object and the radiographic appearance is currently not that of an obstruction. However, the patient should be monitored and if treatment of gastro-intestinal disease is not successful, abdominal ultrasound is recommended. Alternatively, at least one lateral view should be repeated for comparison.



PATIENT

Boots Diccico

SPECIES

Feline

BREED

DSH

SEX

Neutered Male

AGE

6 Years

WEIGHT

17.4 Pounds

INTERPRETED BY

Heike Rudolf, DVM, Dr.
med. Vet., DipECVDI
DVR

IMAGING PERFORMED BY

Mallory Frois

HOSPITAL NAME

The Pet Hospital of
Stratford

REFERRING VET

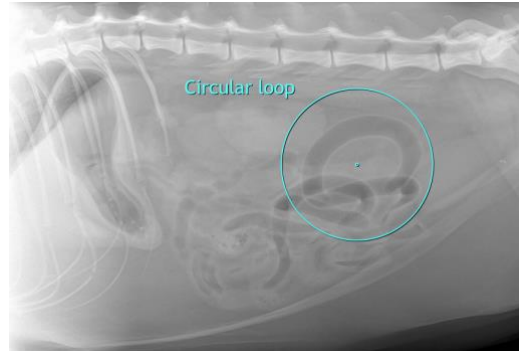
Dr. Claudia Giuliani

INVOICE

36472

DATE

4/3/26



The information and recommendations provided are based on the images presented by the referring veterinarian/sonographer. No evaluation can be communicated regarding pathology that was not visible in the image/video clips provided.

Thank you for this referral. If the clinical or image interpretation does not parallel your findings or if I can be of any further assistance, please contact me.

Heike Rudolf, DVM, Dr. med. vet., DipECVDI, DVR
info@sonopath.com