



PATIENT PRESENTING CLINICAL SIGNS

Abby Cook History: Abby has been a patient with us only since April 18th, 2023, where she presented to us with a bad cough. Her cough is honk-like and happens very often and loudly, ascites. Upon examination, it became clear that Abby has a heart murmur, bilateral cataracts, as well as periodontal disease. It is also noted that she has a collapsed trachea. We took radiographs of the heart. If there are any abnormal findings please let us know as soon as possible.

SPECIES

Canine

RADIOGRAPHIC STUDY OF THE THORAX

BREED

Beagle/Pug Mix

The body condition score is 7/9 with with a large amount of subcutaneous fat in the neck region. The bony structures appear physiological.

The degree of pulmonary expansion is fair at best. The lungs are in contact with the thoracic boundaries and the tips are pointed. The lobar vessels are visible to the tertiary branches. The bronchial tree is thin walled and tapers uniformly towards the periphery.

SEX

Spayed Female

The cranial mediastinum is of physiological size and opacity. The trachea runs parallel to the thoracic vertebrae and is at the same level as the carina.

The cardiac silhouette occupies 85% of the chest height and 3.5 intercostal spaces. No chamber or outflow tract enlargement is obvious.

AGE

15 Years

RADIOGRAPHIC DIAGNOSIS

- Tracheal collapse

INTERPRETED BY

Heike Rudolf, DVM,
Dr. med. Vet.,
DipECVDDI DVR

INTERPRETATION OF THE FINDINGS & FURTHER RECOMMENDATIONS

I can see no obvious cardiomegaly or heart failure.

Tracheal collapse can be due to a weakened dorsal tracheal ligament. Tracheal in combination with bronchial collapse is usually due to an altered cartilage development which may go unnoticed until physical circumstances (such as stress, running, excitement) or disease (e.g. pneumonia, bronchitis, L cardiac enlargement) reduces the ease of airflow. Echocardiography to assess mitral valve and left atrial size is recommended to detect early changes. Bronchoscopy is necessary to identify bronchial collapse and to obtain a BAL. Should an underlying disease be present treatment may improve the clinical signs.

HOSPITAL NAME

Wilson Road VC

REFERRING VET

Dr. Yessa

Obesity is known to worsen clinical signs of cough and impair lung function; weight control is recommended.

INVOICE

22223

TECHNICAL COMMENTS

Non-DICOM images were submitted. The transformation from DICOM to other formats reduces the image quality and only allows limited manipulation of the image. More subtle lesions can thus easily be missed. For the best possible imaging reports, I suggest submitting DICOM images in the future.

DATE

4/28/23



PATIENT

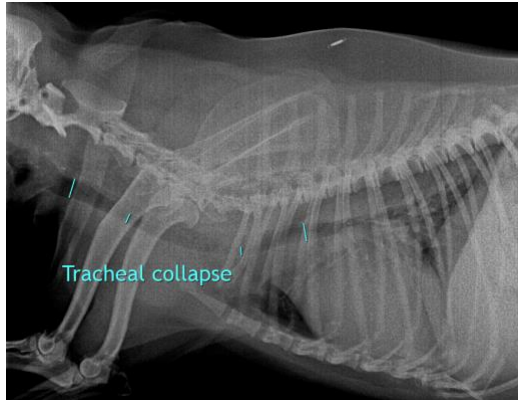
Abby Cook

SPECIES

Canine

BREED

Beagle/Pug Mix



SEX

Spayed Female

AGE

15 Years

The information and recommendations provided are based on the images presented by the referring veterinarian/sonographer. No evaluation can be communicated regarding pathology that was not visible in the image/video clips provided.

Thank you for this referral. If the clinical or image interpretation does not parallel your findings or if I can be of any further assistance please contact me.

Heike Rudorf, DVM, Dr. med. vet., DipECVDI, DVR
dr.h.rudorf@gmail.com

INTERPRETED BY

Heike Rudorf, DVM,
Dr. med. Vet.,
DipECVDI DVR

HOSPITAL NAME

Wilson Road VC

REFERRING VET

Dr. Yessa

INVOICE

22223

DATE

4/28/23