



PATIENT PRESENTING CLINICAL SIGNS

Sandy Black History: Limping on LHL, noticed yesterday- while in the backyard, was non-weight bearing yesterday on LHL. Has a hx of hip dysplasia. Today- partially weight-bearing on LHL
Abnormal PE/Chem/CBC/UA Results: ALP 370 (0-140), rest BW WNL, no cranial drawer/tibial thrust noted upon sedation.

SPECIES

Canine

RADIOGRAPHIC STUDY OF THE PELVIS

The skin surfaces are smooth and the muscles appear to be symmetrically developed.

BREED

English Bulldog

All bones are well mineralized, have a normal trabecular structure and a smooth surface. Cortical-medullary development and differentiation of the long bones are physiological.

SEX

Spayed Female

The centre of both femoral heads is located well lateral to the respective dorsal acetabular edge. The cranial acetabular edges are straight and new bone surrounds the acetabula. Recontouring of both femoral heads and necks is present.

RADIOGRAPHIC DIAGNOSIS

AGE

10 Years

- Severe bilateral HD
- Severe bilateral OA

INTERPRETATION OF THE FINDINGS & FURTHER RECOMMENDATIONS

INTERPRETED BY

Heike Rudorf, DVM,
Dr. med. Vet.,
DipECVDI DVR

The changes represent severe HD with chronic and severe arthrosis. The described acute left sided lameness could be due to a trauma and recurrence of arthritis or may have other reasons. Should the lameness not regress with conservative management, disc disease, myositis, tendinitis and lumbar plexus neuropathy have to be considered. A contrast CT examination can help rule out these differentials.

TECHNICAL COMMENTS

HOSPITAL NAME

St. Catherine's AH

No obvious side marker on VD pelvis

REFERRING VET

Dr. Jui Gokhale

INVOICE

22191

DATE

4/27/23



PATIENT

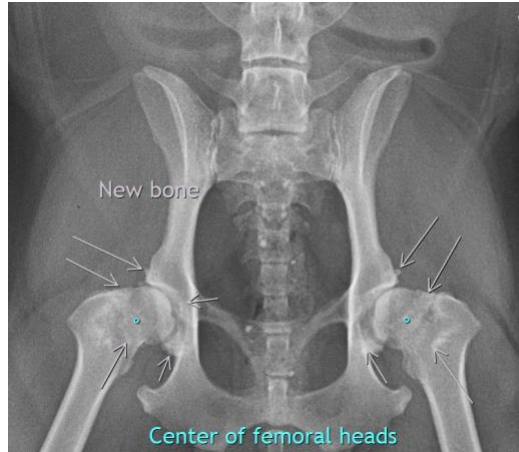
Sandy Black

SPECIES

Canine

BREED

English Bulldog



SEX

Spayed Female

AGE

10 Years

The information and recommendations provided are based on the images presented by the referring veterinarian/sonographer. No evaluation can be communicated regarding pathology that was not visible in the image/video clips provided.

Thank you for this referral. If the clinical or image interpretation does not parallel your findings or if I can be of any further assistance please contact me.

Heike Rudorf, DVM, Dr. med. vet., DipECVDI, DVR
dr.h.rudorf@gmail.com

INTERPRETED BY

Heike Rudorf, DVM,
Dr. med. Vet.,
DipECVDI DVR

HOSPITAL NAME

St. Catherine's AH

REFERRING VET

Dr. Jui Gokhale

INVOICE

22191

DATE

4/27/23