

## PATIENT

Pumpkin Kane

## SPECIES

Feline

## BREED

DSH

## SEX

Spayed Female

## AGE

5 Years

## WEIGHT

13.2 Pounds

## INTERPRETED BY

Heike Rudorf, DVM, Dr.  
med. Vet., DipECVDI  
DVR

## IMAGING PERFORMED BY

Dr. Matt Montresor

## HOSPITAL NAME

Foxfield VS

## REFERRING VET

Dr. Matt Montresor

## INVOICE

36799

## DATE

4/24/26

## PRESENTING CLINICAL SIGNS

History: Congested and s+ x 6 weeks - not evident when P is sleeping, but very prominent when up and moving. Stertorous inspiration on PE 3 weeks ago, rest of exam unremarkable.

No improvement with famciclovir and azithromycin. Recheck PE today - lateral displacement of globe OS with normal retropulsion and no pain on palpation of nose. Stertorous inspiration with decreased airflow through L naris. No masses on oropharyngeal, laryngeal, and otoscopic exams today. Afebrile. FeLV/FIV SNAP neg x 2. CBC/Chem pending.

Abnormal PE/Chem/CBC/UA Results: Lateral displacement of globe OS. Stertorous inspiration with decreased airflow through L naris.

## RADIOGRAPHIC STUDY OF THE HEAD

The surrounding soft tissue structures appear physiological.

Both nostrils are patent and air filled. The left nasal chamber shows an increased soft tissue opacity with loss of clear turbinate structure.

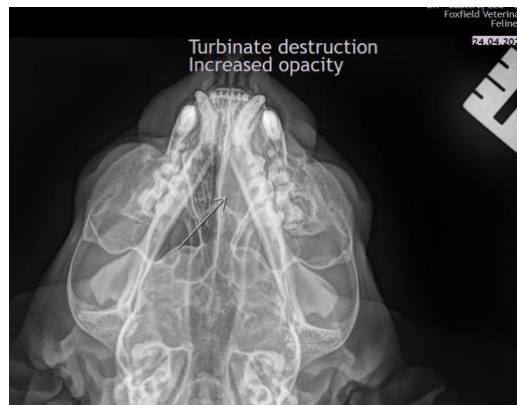## RADIOGRAPHIC DIAGNOSIS

Left nasal chamber

- Soft tissue opacity
- Turbinate destruction

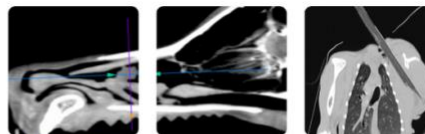
## INTERPRETATION OF THE FINDINGS & FURTHER RECOMMENDATIONS

The changes are highly suggestive of a nasal tumor. However, rhinitis and tumor (e.g., lymphoma) in cats do not necessarily present radiographically different. Thus, CT is recommended to assess severity of the changes and possible lymph node involvement for aspiration. Samples for histology and bacteriology have to be obtained via rhinoscopy.



**The information and recommendations provided are based on the images presented by the referring veterinarian/sonographer. No evaluation can be communicated regarding pathology that was not visible in the image/video clips provided.**

Thank you for this referral. If the clinical or image interpretation does not parallel your findings or if I can be of any further assistance, please contact me.



## PATIENT

Pumpkin Kane

## SPECIES

Feline

## BREED

DSH

## SEX

Spayed Female

## AGE

5 Years

## WEIGHT

13.2 Pounds

## INTERPRETED BY

Heike Rudorf, DVM, Dr.  
med. Vet., DipECVDI  
DVR

## IMAGING PERFORMED BY

Dr. Matt Montresor

## HOSPITAL NAME

Foxfield VS

## REFERRING VET

Dr. Matt Montresor

## INVOICE

36799

## DATE

4/24/26

**Heike Rudorf**, DVM, Dr. med. vet., DipECVDI, DVR  
[info@sonopath.com](mailto:info@sonopath.com)