



## PATIENT

Kole Hennigan

## SPECIES

Canine

## BREED

Labrador Retriever

## SEX

Neutered Male

## AGE

7 Years

## WEIGHT

101

## INTERPRETED BY

Heike Rudorf, DVM, Dr.  
med. Vet., DipECVDI  
DVR

## IMAGING PERFORMED BY

Cottage Grove VC

## HOSPITAL NAME

Cottage Grove VC

## REFERRING VET

Dr. Damewood

## INVOICE

36795

## DATE

4/24/26

## PRESENTING CLINICAL SIGNS

History: Met check. Patient has a large mast cell tumor.

## RADIOGRAPHIC STUDY OF THE THORAX

The body condition score is 6-7/9.

The bony structures appear physiological.

The cranial mediastinum is of physiologic size and opacity. The trachea diverges from the thoracic vertebrae and dips at the carina.

All lung lobes are well aerated and extend to the thoracic boundaries. Pulmonary vessels are well outlined to the tertiary branches. The bronchial tree is thin walled and tapers towards the periphery.

The cardiac silhouette is raised from the sternum by fat (esp. in left lateral recumbency). It occupies 75% of the chest height and 3 intercostal spaces (VHS=11). Chamber or outflow tract enlargement is not obvious.

## RADIOGRAPHIC DIAGNOSIS

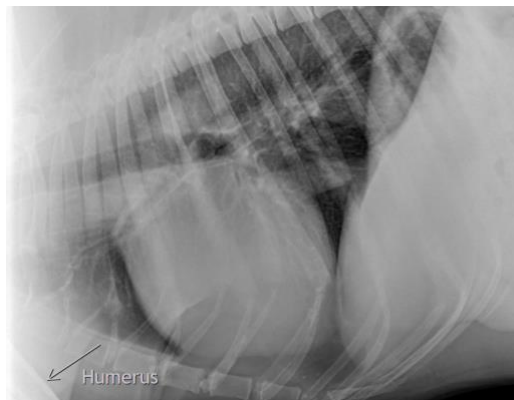- Physiological study

## INTERPRETATION OF THE FINDINGS & FURTHER RECOMMENDATIONS

I can see no pulmonary metastases or lymphadenomegaly. Metastases of local lymph nodes, liver and spleen are possible and thus abdominal ultrasound with FNA of liver and spleen is recommended. In high grade mast cell tumors, all organs and bones can be affected.

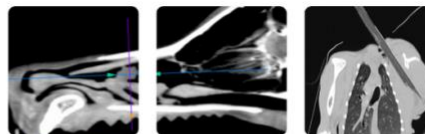
## TECHNICAL COMMENTS

The tips of the cranial lobes are not included. Leg muscles are superimposed onto the cranial lobes.



**The information and recommendations provided are based on the images presented by the referring veterinarian/sonographer. No evaluation can be communicated regarding pathology that was not visible in the image/video clips provided.**

Thank you for this referral. If the clinical or image interpretation does not parallel your findings or if I can be of any further assistance, please contact me.



**PATIENT**

Kole Hennigan

**Heike Rudolf, DVM, Dr. med. vet., DipECVDI, DVR**

[info@sonopath.com](mailto:info@sonopath.com)

**SPECIES**

Canine

**BREED**

Labrador Retriever

**SEX**

Neutered Male

**AGE**

7 Years

**WEIGHT**

101

**INTERPRETED BY**

Heike Rudolf, DVM, Dr.  
med. Vet., DipECVDI  
DVR

**IMAGING  
PERFORMED BY**

Cottage Grove VC

**HOSPITAL NAME**

Cottage Grove VC

**REFERRING VET**

Dr. Damewood

**INVOICE**

36795

**DATE**

4/24/26