



PATIENT

Creed Sudak

SPECIES

Canine

BREED

Rottweiler

SEX

Neutered Male

AGE

9Y

WEIGHT

66.3lbs

INTERPRETED BY

Heike Rudolf, DVM, Dr.
med. Vet., DipECVDDI
DVR

IMAGING PERFORMED BY

Dr. Carlos Abdul-Chani

HOSPITAL NAME

Byram Animal Hospital

REFERRING VET

Dr. Carlos Abdul-Chani

INVOICE

74682

DATE

4-21-26

PRESENTING CLINICAL SIGNS

L pelvic limb lameness

shoulder muscle atrophy

no swelling or pain palpated

RADIOGRAPHS OF SHOULDERS AND ELBOWS

R/L lateral, totaling 3 radiographs provided for interpretation.

RADIOGRAPHIC FINDINGS

The muscle mass appears to be symmetrically developed.

The bones are well mineralized and have smooth, continuous surfaces. Cortico-medullary development and differentiation of the long bones are physiological.

Shoulder L: the joints appear congruent with even subchondral bone surfaces. A small osteophyte is present on the caudal humeral head. A sclerotic line outlines the cranial bicipital groove.

Elbow L: the joints appear congruent with even surfaces. Round to oval shaped, mineral deposits are superimposed onto the caudal olecranon and caudal aspect of the medial condyle.

Shoulder R: the joints appear congruent with even subchondral bone surfaces. A small osteophyte is present on the caudal humeral head. Round to oval mineral opacities are located on the proximal and distal aspects of the greater tubercle.

Elbow R: the joints appear congruent with even surfaces.

RADIOGRAPHIC DIAGNOSIS

L elbow:

- Calcium deposits

L shoulder:

- Sclerosis bicipital groove
- Osteophyte caudal humeral head

Incidental findings:

- R shoulder desmopathy, mild
- R shoulder arthrosis, mild

INTERPRETATION OF THE FINDINGS & FURTHER RECOMMENDATIONS

The changes in both shoulder joints are degenerative in nature, and their significance has to be viewed in line with the results of the clinical examination. The calcium deposits on the left elbow could be located in the surrounding soft tissues (e.g., myositis ossificans) or may be arising from the olecranon. An orthogonal view is necessary for differentiation. Depending on the clinical signs (e.g., pain), comparative ultrasound can be used to assess the surrounding tissue for fluid accumulation. Alternatively, a CT can be performed of both elbows, for comparison.



PATIENT

Creed Sudak

SPECIES

Canine

BREED

Rottweiler

SEX

Neutered Male

AGE

9Y

WEIGHT

66.3lbs

INTERPRETED BY

Heike Rudolf, DVM, Dr.
med. Vet., DipECVDI
DVR

IMAGING PERFORMED BY

Dr. Carlos Abdul-Chani

HOSPITAL NAME

Byram Animal Hospital

REFERRING VET

Dr. Carlos Abdul-Chani

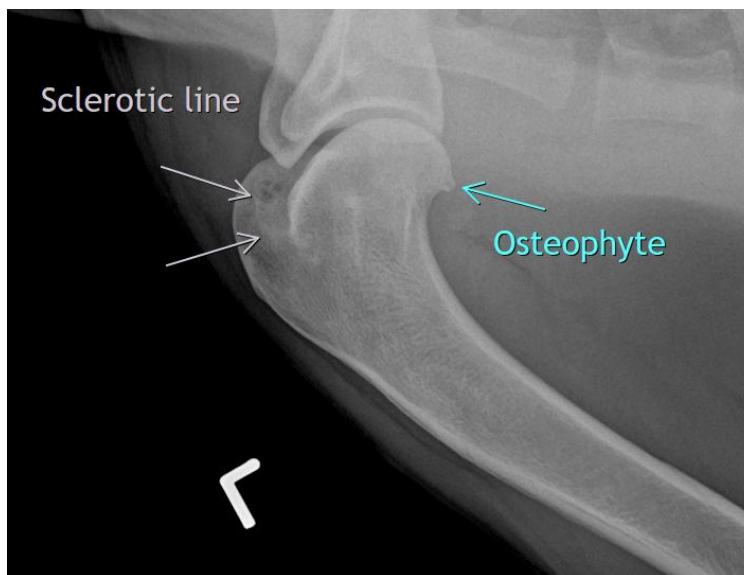
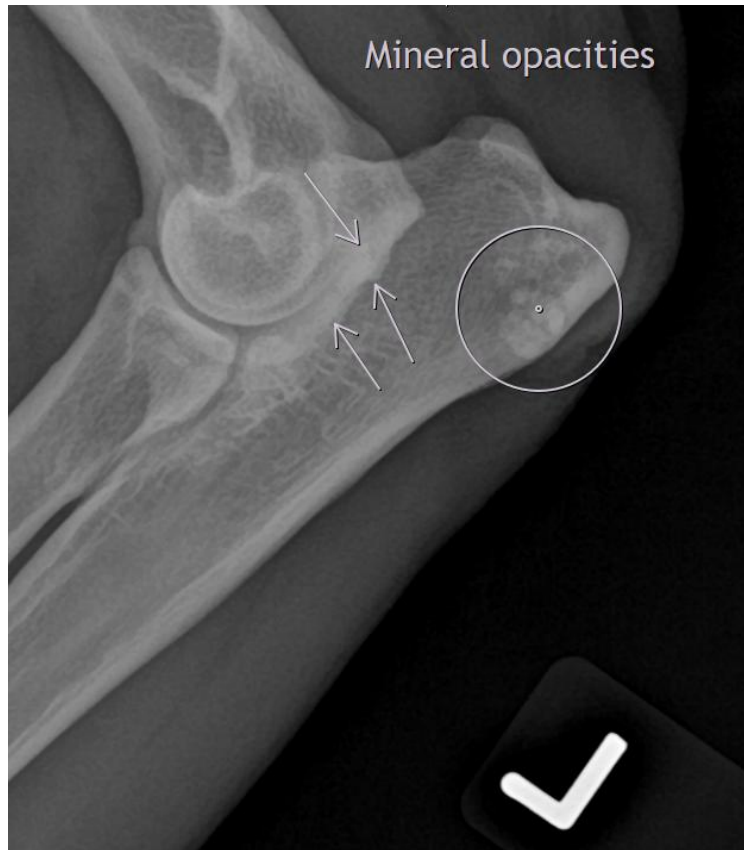INVOICE

74682

DATE

4-21-26

Unilateral muscle atrophy of the foreleg can be due to brachial plexus pathology (e.g., tumor, inflammation). Thus, cross sectional imaging with contrast is recommended.





PATIENT

Creed Sudak

SPECIES

Canine

BREED

Rottweiler

SEX

Neutered Male

AGE

9Y

WEIGHT

66.3lbs

INTERPRETED BY

Heike Rudolf, DVM, Dr.
med. Vet., DipECVDI
DVR

IMAGING PERFORMED BY

Dr. Carlos Abdul-Chani

HOSPITAL NAME

Byram Animal Hospital

REFERRING VET

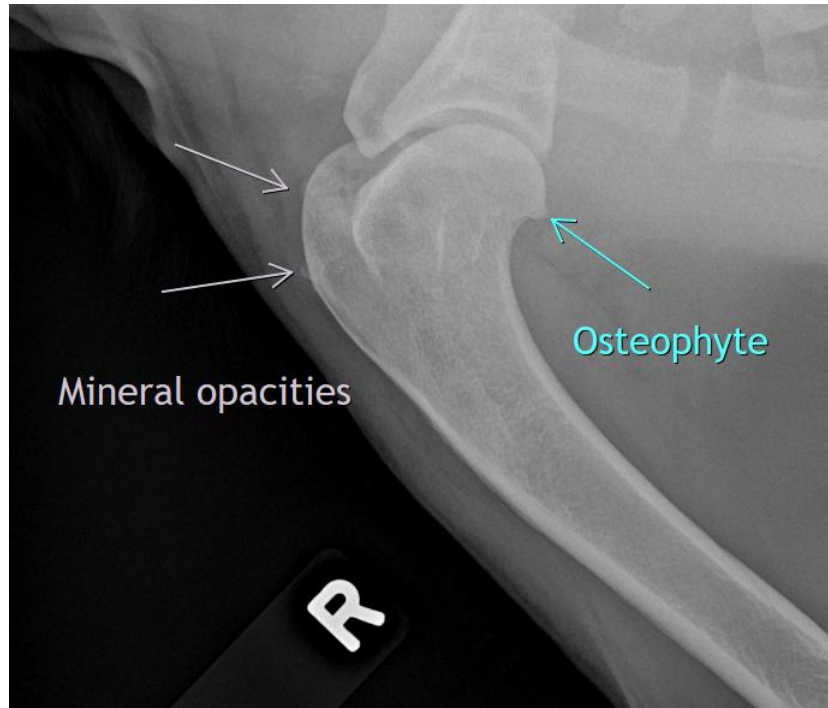
Dr. Carlos Abdul-Chani

INVOICE

74682

DATE

4-21-26



The information and recommendations provided are based on the images presented by the referring veterinarian/sonographer. No evaluation can be communicated regarding pathology that was not visible in the image/video clips provided.

Thank you for this referral. If the clinical or image interpretation does not parallel your findings or if I can be of any further assistance, please contact me.

Heike Rudolf, DVM, Dr. med. vet., DipECVDI, DVR
info@sonopath.com