



PATIENT PRESENTING CLINICAL SIGNS

Grace Nguyen History: Vomiting for 2 days and bloodwork is unremarkable.

RADIOGRAPHIC STUDY OF THE ABDOMEN

SPECIES

Feline

A large amount of intra- and retroperitoneal fat is present which displaces the abdominal structures towards centrally.

The bony structures are within normal limits.

BREED

DSH

The liver is located within the costal arch and the caudo-ventral lobe is pointed. The spleen appears physiological.

SEX

Spayed Female

The stomach contains a small amount of air; distribution and size of the small intestinal loops appear physiological. Colon and rectum contain a moderate amount of unformed fecal matter.

Both renal shadows have a physiological size, shape and opacity; the surfaces are smooth. The bladder is located in the abdominal cavity and contains a moderate amount of homogeneous fluid opacity.

AGE

8 Years

The sublumbar region appears physiological.

RADIOGRAPHIC DIAGNOSIS

- Obesity

INTERPRETED BY

Heike Rudolf, DVM,
Dr. med. Vet.,
DipECVDI DVR

INTERPRETATION OF THE FINDINGS & FURTHER RECOMMENDATIONS

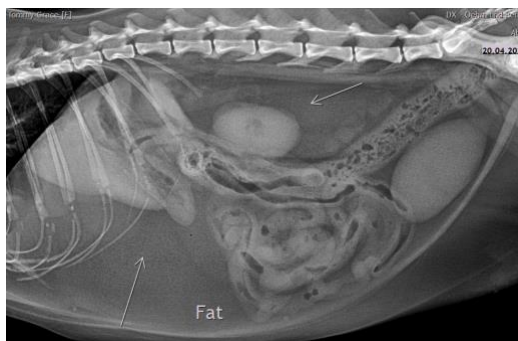
I can see no opaque foreign object or signs of obstruction. Should the cat not respond to conservative management, abdominal ultrasound is recommended to assess gastro-intestinal wall thickness and layering. Weight reduction is recommended.

HOSPITAL NAME

St. Catherine's AH

REFERRING VET

Dr. Boctor



INVOICE

22144

The information and recommendations provided are based on the images presented by the referring veterinarian/sonographer. No evaluation can be communicated regarding pathology that was not visible in the image/video clips provided.

DATE

4/20/23



PATIENT

Thank you for this referral. If the clinical or image interpretation does not parallel your findings or if I can be of any further assistance please contact me.

Grace Nguyen

Heike Rudolf, DVM, Dr. med. vet., DipECVDI, DVR
dr.h.rudorf@gmail.com

SPECIES

Feline

BREED

DSH

SEX

Spayed Female

AGE

8 Years

INTERPRETED BY

Heike Rudolf, DVM,
Dr. med. Vet.,
DipECVDI DVR

HOSPITAL NAME

St. Catherine's AH

REFERRING VET

Dr. Boctor

INVOICE

22144

DATE

4/20/23