



PATIENT

Libby Quiram

SPECIES

Canine

BREED

Rough Collie

SEX

FS

AGE

11Y

WEIGHT

77lbs

INTERPRETED BY

Heike Rudolf, DVM, Dr.
med. Vet., DipECVDI
DVR

IMAGING PERFORMED BY

Technician

HOSPITAL NAME

Northshore Veterinary
Hospital

REFERRING VET

Brita Kiffney

INVOICE

74653

DATE

4-18-26

PRESENTING CLINICAL SIGNS

Radiographs taken 3/20/26 of right elbow (reviewed Heike Rudolf, DVM, Dr. med. Vet., Dip ECVDI DVR) showed Lucency olecranon

- Cortical thinning

She is stiff on all four limbs, not sensitive over the right elbow

Abnormal PE/Chem/CBC/UA Results: Recheck radiographs to evaluate for any changes in right elbow in comparison to 3/20/26

RADIOGRAPHS OF THE ELBOWS

R/L lateral and VD, totaling five radiographs provided for interpretation.

RADIOGRAPHIC FINDINGS

Elbow R: the oval lucency is still present but is now surrounded by a thin, radiopaque line. The cortex is of physiological thickness and trabecular structure now separates the lucency from the cortex.

RADIOGRAPHIC DIAGNOSIS

- Possible bone cyst

INTERPRETATION OF THE FINDINGS & FURTHER RECOMMENDATIONS

The lucency is much better defined; the now visible thin, radiopaque rim suggests a bone cyst.

Stiffness on all four legs without radiographic bone changes can also be due to infectious diseases such as Borreliosis; joint taps are then recommended. Other infections that affect the neuromuscular system are protozoal, bacterial (e.g., clostridial), rickettsial, or parasitic (e.g. Trypanosomiasis). Autoimmune mediated diseases should be ruled out. Anti-inflammatory medications may be tried. Pain management should be considered.



PATIENT

Libby Quiram

SPECIES

Canine

BREED

Rough Collie

SEX

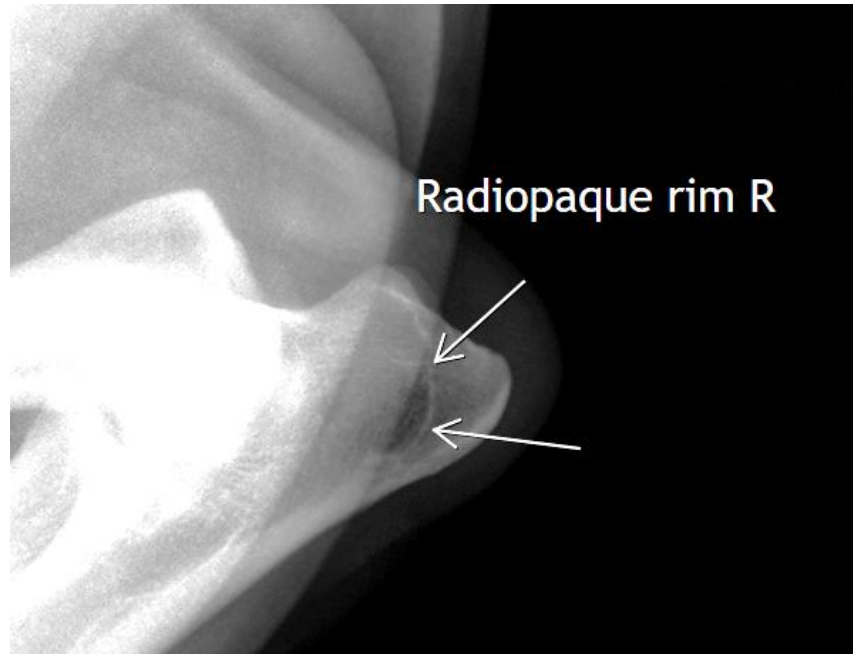
FS

AGE

11Y

WEIGHT

77lbs



INTERPRETED BY

Heike Rudolf, DVM, Dr.
med. Vet., DipECVDI
DVR

IMAGING PERFORMED BY

Technician

HOSPITAL NAME

Northshore Veterinary
Hospital

REFERRING VET

Brita Kiffney

INVOICE

74653

DATE

4-18-26

The information and recommendations provided are based on the images presented by the referring veterinarian/sonographer. No evaluation can be communicated regarding pathology that was not visible in the image/video clips provided.

Thank you for this referral. If the clinical or image interpretation does not parallel your findings or if I can be of any further assistance, please contact me.

Heike Rudolf, DVM, Dr. med. vet., DipECVDI, DVR
info@sonopath.com