



PATIENT

Rusty Davis

SPECIES

Canine

BREED

Shepherd

SEX

Neutered Male

AGE

6 Male

WEIGHT

42.2 Pounds

INTERPRETED BY

Heike Rudorf, DVM, Dr.
med. Vet., DipECVDI
DVR

IMAGING PERFORMED BY

Kevin

HOSPITAL NAME

Elizabeth AH

REFERRING VET

Kim Allyn, DVM

INVOICE

36639

DATE

4/17/26

PRESENTING CLINICAL SIGNS

History: Ate push pins last night, Vomited once last night

Abnormal PE/Chem/CBC/UA Results: PE: WNL

RADIOGRAPHIC STUDY OF THE ABDOMEN

The body condition score is 6/9 with smooth, alternating layers of fat and soft tissue opacity.

The bony structures are within normal limits.

The abdominal organs are surrounded by little fat; diaphragm and abdominal wall are intact.

The stomach is moderately distended with food. Distribution and size of the small intestinal loops appear physiological. The colon contains unformed feces. A thin, approx. 4.6cm long, metallic object is located in the rectum.

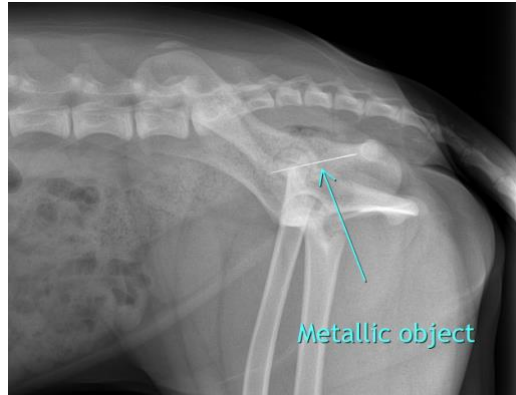
All other visible structures appear physiological.

RADIOGRAPHIC DIAGNOSIS

- Needle in rectum

INTERPRETATION OF THE FINDINGS & FURTHER RECOMMENDATIONS

I can see no signs of metallic foreign objects in the GIT, other than in the rectum.



The information and recommendations provided are based on the images presented by the referring veterinarian/sonographer. No evaluation can be communicated regarding pathology that was not visible in the image/video clips provided.

Thank you for this referral. If the clinical or image interpretation does not parallel your findings or if I can be of any further assistance, please contact me.

Heike Rudorf, DVM, Dr. med. vet., DipECVDI, DVR
info@sonopath.com